



# American Journal of Anesthesia & Clinical Research

## Case Report

# A Case of Undiagnosed Hyperthyroidism Detected in Preoperative Anesthesia & Clinical Research Consultation - ③

Ouchi K\*

*Department of Dental Anesthesiology, Kyushu University Graduate School, Japan*

**\*Address for Correspondence:** Kentaro Ouchi, Department of Dental Anesthesiology, Field of Maxillofacial Diagnostic and Surgical Sciences, Faculty of Dental Science, Kyushu University Graduate School, 3-1-1 Maidashi, Higashi-ku, Fukuoka 812-8582, Japan, Tel: +81-92-641-1151; Fax: +81-92-642-6481; Email: ken2006anes@yahoo.co.jp

**Submitted:** 19 November 2015; **Approved:** 28 December 2015; **Published:** 31 December 2015

**Citation this article:** Ouchi K. A Case of Undiagnosed Hyperthyroidism Detected in Preoperative Anesthesia & Clinical Research Consultation. American J Anesth Clin Res. 2015;1(1): 001-004.

**Copyright:** © 2015 Ouchi K. This is an open access article distributed under the Creative Commons Attribution License, which permits unrestricted use, distribution, and reproduction in any medium, provided the original work is properly cited.



## ABSTRACT

This report describes patients for whom the preoperative, anesthesia consultation led to postponing planned surgery because of important, undiagnosed health problems.

At the preoperative anesthesia consultation, fever, hidrosis and tachycardia during hospitalization were observed. Hence, family medical history was asked. In family history, his mother had a diagnosis of Basedow disease. Hence, thyroid function test was performed. In thyroid function test, elevated free thyroid hormone concentrations were observed. Hence, postponing planned surgery was decided. In thyroid autoantibody test, elevated TRAb (TSH receptor antibody), antithyroglobulin antibody and thyroid peroxidase antibody were observed. Thus, Basedow disease (Graves' disease) was diagnosed.

Unsuspected thyroid disease should be borne in mind when a hypermetabolism patient enters the surgery. This case-report emphasizes the value of a preoperative anesthesia consultation.

**Keywords:** Anesthesia consultation, Perioperative period, General anesthesia, Basedow disease, Graves' disease

## INTRODUCTION

Preoperative consultation is an important intervention that has most benefits for patients undergoing surgery [1-3]. Surgical operations are one of the commonly cited precipitating factors for a thyroid crisis. Even anesthesia induction is the precipitating factors for a thyroid crisis [4].

A 23-years old man with no history presents at the preoperative anesthesia consultation for general anesthesia for teeth extraction. At the preoperative anesthesia consultation, 1 day before surgery, fever, hidrosis and tachycardia during hospitalization. Hence, family medical history was asked. In family history, his mother had a diagnosis of Basedow disease (Graves' disease). Hence, thyroid function test was performed. In thyroid function test, elevated free thyroid hormone concentrations were observed. Thus, postponing planned surgery was decided, and consulted internal medicine. Basedow disease was diagnosed.

This case-report emphasizes the value of a preoperative anesthesia consultation.

## CASE REPORT

A 23-years old man with no history presents at the preoperative anesthesia consultation for general anesthesia for teeth extraction. Blood test, electrocardiogram and chest radiography were performed, 12 days before scheduled surgery. Because mild elevated AST and ALT were observed, liver function test was performed again, 8 days before scheduled surgery. He is hospitalized, 4 days before scheduled surgery. At the preoperative anesthesia consultation, immediately after patient hospitalization, there were no abnormalities in diagnostic interview, physical finding, electrocardiogram, and chest radiography (Figure 1). In perioperative laboratory finding, mild elevated AST and ALT were observed (Table 1).

At the second preoperative anesthesia consultation, 1 day before scheduled surgery, fever, hidrosis and tachycardia were observed. During hospitalization, heart rate was 100-108 beats/min (maximum value - minimum value), systolic blood pressure was 115-136 mmHg, diastolic blood pressure was 62-81 mmHg and body temperature was 36.9-37.3 degrees. Hence, family medical history was asked. In family history, his mother had a diagnosis of Basedow disease. The swelling of patient's thyroid gland on an ocular inspection and palpation was not observed. Proptosis on an ocular inspection was not observed. Thyroid function test was performed. In thyroid function test,

elevated free thyroid hormone concentrations were observed (Table 2). Hence, postponing planned surgery was decided, and consulted internal medicine.

Thyroid autoantibody test was performed in internal medicine. In thyroid autoantibody test, elevated TRAb (TSH receptor antibody), antithyroglobulin antibody and thyroid peroxidase antibody were observed (Table 3). Thus, Basedow disease was diagnosed.

## DISCUSSION

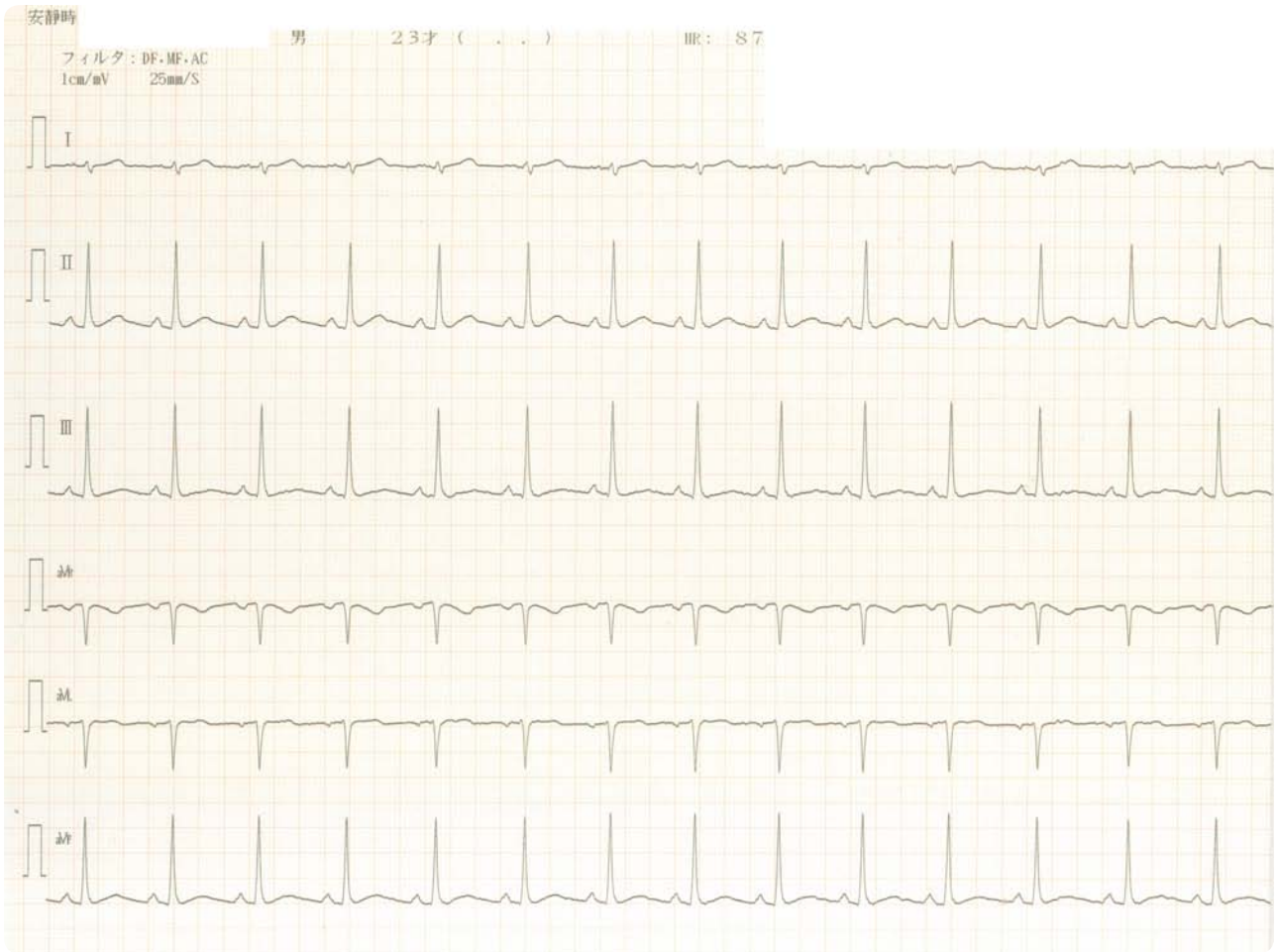
Thyroid storm or crisis is a life-threatening syndrome. Thyroid storm can be precipitated by anesthesia and surgery [5]. Hence, in Basedow disease patient, preoperative treatment is necessary. And, undiagnosed Basedow disease must find and diagnose, in preoperative period. Our patient had only minor symptoms of Basedow disease. He had only sweating, mild elevated hepatic function value and tachycardia at anesthesia consultation. After investigating, Basedow disease was diagnosed.

Differential diagnosis of thyroid storm during operation includes a malignant hyperthermia, neuroleptic malignant syndrome, anaphylactic reaction, brain insult or pheochromocytoma [5]. The treatment of thyroid storm should not wait. Firstly, antithyroid drug should be given to decrease the production of thyroid hormones. Second, the systemic manifestations of tachycardia, fever and hypovolemia should be treated. Third, finally, the precipitating factor should be treated [5].

The autoimmune thyroid diseases comprising Basedow disease and Hashimoto's thyroiditis are genetic diseases [6]. In this case, patient's mother has Basedow disease. Family history, hypermetabolism (such as tachycardia, fever and reduced serum cholesterol) and elevated liver function (lactate dehydrogenase (LDH), aspartate transaminase (AST), alanine aminotransferase (ALT) and alkaline phosphatase (ALP)) suspected Basedow disease. At preoperative anesthesia consultation, anesthesiologist noticed patient's family history and hypermetabolism. Hence, anesthesiologist suspected Basedow disease. This case-report emphasizes the value of a preoperative anesthesia consultation.

## CONCLUSION

Unsuspected thyroid disease should be borne in mind when a hypermetabolism patient consults preoperative anesthesia consultation. This case-report emphasizes the value of a preoperative anesthesia consultation.



**Figure 1: Preoperative electrocardiogram.** Electrocardiogram was performed, 12 days before surgery. There were no abnormalities. Heart rate recorded was 87 beats/min.

**Table 1: Blood chemical analysis.**

	Preoperative value			Standard value
	Twelve days before scheduled surgery	Eight days before scheduled surgery	One days before scheduled surgery	
Total cholesterol	171 (reduction)	108 (reduction)	91 (reduction)	128-219 mg/dL
Triglyceride	61	102	95	30-149 mg/dL
AST	36 (elevation)	37 (elevation)	28	13-33 IU/L
ALT	69 (elevation)	80 (elevation)	65 (elevation)	6-30 IU/L
LDH	153			119-229 IU/L
ALP	227			115-359 IU/L
γ-GTP	33v	33	31	10-47 IU/L
Cholinesterase	368			214-466 IU/L
Total protein	6.7			6.7-8.3 g/dL
Total bilirubin	0.9			0.3-1.2 mg/dL

**Table 2: Thyroid function test.**

	Preoperative value	Standard value
FT4	>7.77 (elevation)	0.9-1.7 pg/dl
FT3	26.0 (elevation)	2.3-4.0 pg/ml
TSH	0.01 (reduction)	0.5-5.0 μIU/ml

**Table 3:** Thyroid autoantibody test.

	Preoperative value	Standard value
TSH receptor antibody	4.2 (elevation)	<1.0 IU/ml
Anti thyroglobulin antibody	66 (elevation)	<28 IU/ml
Anti thyroid peroxidase antibody	33 (elevation)	<16 IU/ml

## ACKNOWLEDGMENTS

I would like to thank Dr. Yozo Manabe for he helped with anesthesia consultation.

## REFERENCES

1. Amar S, Van Boven M, Rooijackers H, Momeni M. Massive postoperative pulmonary embolism in a young woman using oral contraceptives: the value

of a preoperative anesthetic consult. *Acta Anaesthesiol Belg.* 2014; 65: 73-75.

2. Thilen SR, Wijeyesundera DN, Treggiari MM. Preoperative Consultations. *Anesthesiol Clin.* 2016; 34: 17-33.
3. Ouchi K, Uno H, Koga Y. [Abnormal hypertension during undiagnosed pheochromocytoma resection surgery —General anesthesia for the veiled-type pheochromocytoma—]. *J Clin Anesth (Jpn).* 2008; 32: 1801-1805.
4. Bennett MH, Wainwright AP. Acute thyroid crisis on induction of anaesthesia. *Anaesthesia.* 1989; 44: 28-30.
5. Hirvonen EA, Niskanen LK, Niskanen MM. Thyroid storm prior to induction of anaesthesia. *Anaesthesia.* 2004; 59: 1020-1022.
6. Villanueva R, Tomer Y, Greenberg DA, Mao C, Concepcion ES, Tucci S, et al. Autoimmune thyroid disease susceptibility loci in a large Chinese family. *Clin Endocrinol (Oxf).* 2002; 56: 45-51.