



American Journal of Anesthesia & Clinical Research

Case Report

Regional Anesthetic Technique for a Patient with Neurofibromatosis Type 1 and an Unusual Appearance of the Lower Extremity Nerves - Ⓜ

Tolga Suvar^{1*}, Mark Stevens¹, Gregory Mehaffey¹, Arjav Shah¹ and Mikhaela Arambulo²

¹University of Arkansas for Medical Sciences, Department of Anesthesiology

²University of Arkansas for Medical Sciences, College of Medicine

***Address for Correspondence:** Tolga Suvar, University of Arkansas for Medical Sciences, Department of Anesthesiology, 4301 W Markham St, Slot 515, Little Rock, AR 72227, Tel: + (516)-376-8419; Fax: + (501)-686- 7059; E-mail: Tsuvar@uams.edu; TolgaSuvar@gmail.com

Submitted: 31 October 2017; Approved: 13 November 2017; Published: 15 November 2017

Cite this article: Suvar T, Stevens M, Mehaffey G, Shah A, Arambulo M. Regional Anesthetic Technique for a Patient with Neurofibromatosis Type 1 and an Unusual Appearance of the Lower Extremity Nerves. Am J Anesth Clin Res. 2017;3(2): 034-036.

Copyright: © 2017 Suvar T, et al. This is an open access article distributed under the Creative Commons Attribution License, which permits unrestricted use, distribution, and reproduction in any medium, provided the original work is properly cited.

ABSTRACT

Objective: This case demonstrates challenges associated with regional anesthesia and demonstrates safe anesthetic techniques for a surgical procedure in an NF1 patient.

Case Report: A 27-year-old patient with neurofibromatosis 1 had developed a rapidly growing mass in his right foot that required biopsy. History of multiple cranio-cervical-thoracic fusions, scoliosis, and limited neck extension raised concerns for a difficult airway.

Conclusion: In place of the popliteal and saphenous nerve blocks, the surgical procedure was successfully managed with an ankle block using low volume 0.5% bupivacaine as we targeted the right superficial, deep, and tibial nerves, with a subsequent field block performed around the saphenous nerve.

Keywords: Regional anesthesia; Neurofibromatosis 1

INTRODUCTION

Neurofibromatosis type 1 (NF1) is predominantly a neurocutaneous disorder, but can affect different organ systems; numerous considerations must be made in a NF1 patient who will undergo anesthesia. We report a case of a soft tissue biopsy in a 27-year-old Caucasian male with a history of NF1 complicated by multiple cervical spinal fusion surgeries with significant airway concerns. The decision was made to proceed with a regional anesthetic technique with moderate sedation.

CASE REPORT

A 27-year-old male with a past medical history of neurofibromatosis type 1 presented to the clinic for a 3-month history of a rapidly growing mass located on the dorsum of his right foot. MRI was performed and revealed a 3.8 x 4 x 3.8 mass, appearing to involve the 2nd and 3rd metatarsals. Surgical biopsy of the mass was planned. On pre-operative assessment, patient had a Mallampati score of 2, but has had numerous cranio-cervical thoracic spine fusions due to neuromuscular scoliosis, with significantly limited neck extension rendering him a difficult endotracheal intubation. The decision was made to proceed with regional anesthesia combined with intravenous sedation. The patient was pre-medicated with 2 mg of midazolam. Using a linear ultrasound probe, we attempted a sciatic popliteal and adductor canal nerve blocks under ultrasound guidance when we noticed several neurofibromas in his popliteal nerve (Figure 1). Given this aberrant anatomy, we decided to take a more distal approach and proceed with an ankle block using a 22G short-bevel needle. The right superficial and deep peroneal and tibial nerves were visualized and blocked with bupivacaine, 0.5% (3 mL around each nerve) under ultrasound guidance. A field block was also performed on the right saphenous nerve using bupivacaine, 0.5%, 5 mL. Given the location of the surgery, a sural nerve block was not performed. Once in the operating room, a propofol infusion was started and the surgical procedure lasted less than two hours. Biopsy of the mass revealed spindle cell proliferation within a fibrous background and areas of myxoid change, with no significant mitotic activity and negative for S100 protein, suggestive of low grade malignant peripheral nerve sheath tumor.

DISCUSSION

Neurofibromatosis type 1 (NF1) is an autosomal dominant neurocutaneous condition caused by an NF1 gene mutation, resulting in decreased activity or nonfunctional neurofibromin protein. It affects 1 in 2600 to 3000 individuals. Clinical manifestations include cafe-au lait spots, axillary freckling, Lisch nodules, optic gliomas, and

neurofibromas. Neurofibromas are the most common tumor found in NF1 patients. They can be cutaneous, plexiform, or nodular, and they can undergo a malignant transformation with a risk of 5-13% [1].

NF1 may involve multiple organ systems, and therefore raise anesthetic concerns during surgical procedures. Neurofibromas may be present in the airway which can make intubation difficult [2].

Lovell, et al. [3] reports a case of cervical vertebrae dislocation that was discovered post surgery in an asymptomatic NF1 patient with multiple cervical neurofibromas. There must be a consideration for a radiologic examination prior to anesthesia for NF1 patients with a history of cervical surgery to assess for any unknown cervical dislocations. Vertebral deformities, like scoliosis present in our patient, or neurofibromas in the spinal cord may also complicate spinal or extradural blocks. Other considerations include undiagnosed neurofibromas in the lungs and GI tract, hypertension, renal artery stenosis, and pheochromocytoma [2].

Shahid and Sebastian [4] report a case of lower limb wound debridement in a 66-year-old NF1 patient successfully managed with a femoral and sciatic nerve block. Another case was reported by Bagam, et al. [5] of a 60-year-old female with NF1 who needed dynamic hip screw fixation of the left femur and intramedullary interlocking nail for the humerus. The surgical procedures were managed with a subarachnoid block and a brachial plexus block, respectively. Given this patient's extensive history of multiple cranio-cervical-thoracic fusions surgeries, NF1 complicated by scoliosis, and neurofibromas extensively found throughout his body, a decision was made to proceed with a regional block as demonstrated by various case reports to be the safest anesthetic option. As of note, a neuroaxial technique

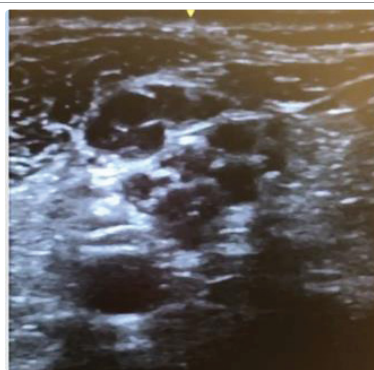


Figure 1: Hypoechoic structures within the popliteal nerve, superficial to the popliteal artery



was considered but not performed as the patient's history of scoliosis would have made this anesthetic significantly more challenging. We utilized ultrasound, as demonstrated by Desai, et al. [6] to safely guide popliteal nerve blockade. Our ultrasound scan of the popliteal fossa using a linear probe demonstrated multiple hypoechoic structures within the popliteal nerve. These hypoechoic structures were concerning for neurofibromas, as seen in the report by Rocco and Rosenblatt [7]. The common peroneal and tibial nerve branching was not easily identified as they should have been seen converging from the popliteal nerve. As seen in figure 1, there were concerns for having adequate local anesthetic infiltration of the endoneurium as well as considerations for nerve damage and an insult to the neuromas with an inadvertent puncture of the nerve by the 22G short-bevel needle. A more caudal approach was utilized to block the right superficial and deep peroneal nerves, and tibial nerve as seen in figure 2.

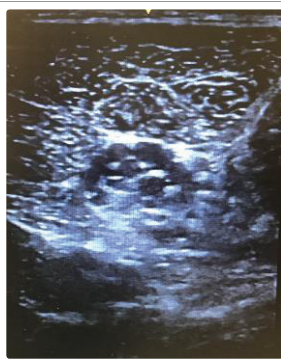

Figure 2: Tibial nerve.

Numerous challenges are faced when administering anesthetics to patients with NF1; significant airway concerns in our patient led to a regional technique with mild sedation as a safer alternative to general anesthesia for lower extremity surgery. While there were concerns about performing regional blocks at the saphenous and popliteal level, a more distal approach can be used in the presence of neurofibromas in major peripheral nerves.

REFERENCES

1. Korf BR. Neurofibromatosis type 1 (NF1): Pathogenesis, clinical features, and diagnosis. UpToDate. Waltham, MA: UpToDate Inc. 2017. <https://goo.gl/vFFUq9>
2. Hirsch NP, Murphy A, Radcliffe JJ. Neurofibromatosis: Clinical presentations and anaesthetic implications. *Br J Anaesth.* 2001; 86: 555-564. <https://goo.gl/LPTdmB>
3. Lovell AT, Alexander R, Grundy EM. Silent, unstable, cervical spine injury in multiple neurofibromatosis. *Anaesthesia.* 1994; 49: 453-454. <https://goo.gl/JzqxXa>
4. Shahid M, Sebastian B. A safe alternative in neurofibromatosis for lower limb surgeries: combined femoral and sciatic nerve block. *J Clin Diagn Res.* 2015; 9: 03-04.
5. Bagam KR, Vijaya DS, Mohan K, Swapna T, Maneendra S, Murthy S. Anaesthetic considerations in a patient with von recklinghausen neurofibromatosis. *J Anaesthesiol Clin Pharmacol.* 2010; 26: 553-554. <https://goo.gl/JJ9HV2>
6. Desai A, Carvalho B, Hansen J, Hill J. Ultrasound-Guided popliteal nerve block in a patient with malignant degeneration of neurofibromatosis 1. *Case Rep Anesthesiol.* 2012; 2012:753769. <https://goo.gl/5jPLsW>
7. Rocco ML, Rosenblatt MA. Ultrasound-guided peripheral nerve block in a patient with neurofibromatosis. *Reg Anesth Pain Med.* 2011; 36: 88-89. <https://goo.gl/yfKPPe>