



International Journal of Clinical Cardiology & Research

Case Report

Subacute Thrombosis of Left Main Coronary Artery After Transcatheter Aortic Valve Implantation - @

Cristina Aguilera Agudo^{1*}, Jorge Baena Herrera¹, Juan Francisco Oteo Dominguez² and Francisco Javier Goicolea Ruigómez³

¹Resident in Cardiology, Hospital Universitario Puerta de Hierro, Majadahonda

²Cardiologist consultant, Invasive Cardiology, Hospital Universitario Puerta de Hierro, Majadahonda

³Director of Invasive Cardiology Hospital Universitario Puerta de Hierro, Majadahonda

***Address for Correspondence:** Cristina Aguilera Agudo, Calle Manuel de Falla, 1, 28222, Majadahonda Spain, Tel: +911-916-000; ORCID ID: 0000-0002-8884-6478; E-mail: aguciri@correo.ugr.es; cristinaaguilera.agudo@gmail.com

Submitted: 28 November 2018; **Approved:** 04 January 2019; **Published:** 07 January 2019

Cite this article: Aguilera Agudo C, Baena Herrera J, Oteo Dominguez JF, Goicolea Ruigómez FJ. Subacute Thrombosis of Left Main Coronary Artery After Transcatheter Aortic Valve Implantation. Int J Clin Cardiol Res. 2019;3(1): 001-002.

Copyright: © 2019 Agudo CA, et al. This is an open access article distributed under the Creative Commons Attribution License, which permits unrestricted use, distribution, and reproduction in any medium, provided the original work is properly cited.

ISSN: 2639-3786

ABSTRACT

Obstruction of the coronary ostium after Transcatheter Aortic Valve Replacement (TAVR) is a rare complication, with an estimated incidence of approximately 0.66% [1].

The timing of this complication has been established in a bimodal way with either early (1st week) or late (> 60 days) occlusions with no events in between (subacute) [2].

However, we would like to describe a subacute development of this complication, with an unusual clinical presentation.

INTRODUCTION

Transcatheter aortic valve replacement has been increasing during the last years due to the high prevalence of symptomatic aortic stenosis and the high-risk score of the patients with this condition. Although it usually implies fewer complications for patients including shorter hospital stays, it is with the implantation in large populations that we are discovering some very rare complications.

One of the most important of these complications is coronary obstruction. Since the first case description, some predictors' factors have been described, however, it is still a difficult scenario with non-easy solutions even when you considered it.

CLINICAL CASE

An 86-year-old man presented to the emergency department with progressive dyspnea and congestive heart failure, after transfemoral TAVR. A 26 without balloon pre-dilation and, subsequent (due to cranial displacement of the 1st one) 29-mm Portico™ (St. Jude Medical) valves had been successfully implanted 36 days earlier. At initial evaluation, he showed severe deterioration of left ventricular ejection fraction (15% vs 35%), elevated troponin and NT-proBNP and a new left bundle branch block in the electrocardiogram. Despite the fact that the patient was asymptomatic for angina pectoris and hemodynamically stable, we performed an emergent angiography. Although selective engagement of the coronary arteries was not possible, there was an apparent adequate filling of both. Twenty-

four hours later, the patient suffered a cardiorespiratory arrest in electromechanical dissociation and he finally died.

On autopsy, the left main coronary ostia was partially occluded by a calcified native leaflet leaving a crescent shaped orifice. Moreover, the first Portico valve, cranially displaced with the sealing cuff reaching the sinotubular junction, displayed an evident imprint on ascending aorta, as may be observed in the image (Figure 1).

DISCUSSION

We consider this case particularly interesting due to the timing of presentation and predominant symptoms of congestive heart failure. Accordingly, in the presence of symptoms, we want to emphasize the importance of maintaining a high level of suspicion of coronary obstruction after TAVR, not only early after the procedure or as late presentation.

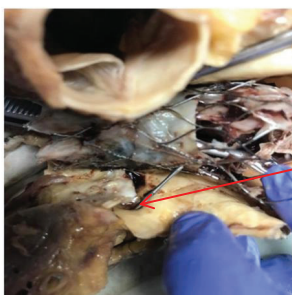
The Portico™ Transcatheter Aortic Heart Valve approved in 2015 for the treatment of aortic stenosis is a relatively newly-accepted device which is fully repositionable and retrievable in situ. After the use of Portico valve, coronary obstruction has been described to be of 4.2% in the first week and of 14.3% after this time [2].

Other trials estimated a prevalence of 5.2% in the first 30 days [3].

It is especially important in patients with known risk factors (valve in valve implantation, heavily calcified aortic valve or self-expandable devices) [4] for coronary occlusion due to its potential fatal outcomes.

REFERENCES

1. Bourantas CV, Serruys PW. Evolution of transcatheter aortic valve replacement. *Circ Res*. 2014; 114: 1037-1051. <https://goo.gl/2cfSbK>
2. Jabbour RJ, Tanaka A, Finkelstein A, Mack M, Tamburino C, Van Mieghem N, et al. Delayed Coronary Obstruction After Transcatheter Aortic Valve Replacement. *J Am Coll Cardiol*. 2018; 71: 1513-1524. <https://goo.gl/ebLX6g>
3. Dvir D, Leipsic J, Blanke P, Ribeiro HB, Kornowski R, Pichard A, et al. Coronary obstruction in transcatheter aortic valve-in valve implantation: preprocedural evaluation, device selection, protection, and treatment. *Circ Cardiovasc Interv*. 2015; 8: e002079. <https://goo.gl/HhvxTt>
4. Dvir D, Leipsic J, Blanke P, Ribeiro HB, Kornowski R, Pichard A, et al. Coronary obstruction in transcatheter aortic valve-in-valve implantation: preprocedural evaluation, device selection, protection, and treatment. *Circ Cardiovasc Interv*. 2015; 8: pii: e002079. <https://goo.gl/o8hf4L>



Punch across the coronary ostium.

Figure 1: Image of the necropsy showing the ostium of main coronary artery (stiletto) with the imprint of the valves.