



International Journal of Case Reports & Short Reviews

Case Report

Female Urethral Cavernous Hemangioma: an Unusual Cause of Hematuria -

Shringarpure S. Shrikant^{1*}, Shringarpure S. Sanish², Inamdar M.
Ravindra³, Kulkarni R. Sourabh⁴ and Patkar VS⁵

¹Consultant Urologist, Shreeyash Hospital, New Panvel, Maharashtra, India

²Anesthetist, Shreeyash Hospital, New Panvel, Maharashtra, India

³Consultant Gynecologist, Shreeyash Hospital, New Panvel, Maharashtra, India

⁴Consultant Gynecologist, Shreeyash Hospital, New Panvel, Maharashtra, India

⁵Consultant Histopathologist, Patkar Laboratories, Panvel, Maharashtra, India

***Address for Correspondence:** Shringarpure Sanish Shrikant, Consultant Urologist, Shreeyash Hospital, New Panvel, Maharashtra, India, E-mail: sanishuro@yahoo.com

Submitted: 31 July, 2017; **Approved:** 24 August, 2017; **Published:** 26 August, 2017

Citation this article: Shringarpure SS, Shringarpure SS, Inamdar MR, Kulkarni RS. Female Urethral Cavernous Hemangioma: an Unusual Cause of Hematuria. Int J Case Rep Short Rev. 2017;3(3): 046-046.

Copyright: © 2017 Shringarpure SS, et al. This is an open access article distributed under the Creative Commons Attribution License, which permits unrestricted use, distribution, and reproduction in any medium, provided the original work is properly cited.

ABSTRACT

Hemangiomas are benign vascular tumors, most commonly involving the liver and skin whereas involvement of genitourinary system is rare. Urethral involvement is rare and only few cases have been reported in the literature. Only few cases of hemangioma in the female urethra have been reported. We report a case of hemangioma in a 60 year old female who presented with intermittent urethral bleeding. Physical examination revealed an erythematous, polypoidal mass surrounding the urethral meatus. We performed a surgical resection of the tumor with fulguration of the base with diathermy under spinal anesthesia. The post-operative course was uneventful. Final diagnosis on histopathology showed cavernous type of urethral hemangioma. This case has been presented for its rare occurrence in females and to update through a review of literature aspects of the diagnosis and therapeutic care of urethral hemangioma.

Keywords: Hemangioma; Female; Urethra; Hematuria

INTRODUCTION

Bleeding per urethra is a common urological symptom and needs urgent evaluation to rule out malignant etiology. Hemangiomas are mostly found in the liver and skin [1]. Genitourinary localisations are rare and have been rarely reported in the prostate, bladder, ureter and perineum [2]. Urethral hemangiomas are predominantly seen in males with only handful of case reports described in females [3]. It has been suggested that they originate from unipotent angioblastic cells which fail to develop into normal blood vessel. The most common type is cavernous hemangioma. The cardinal sign is bleeding, either gross or microscopic or urethrorrhagia. We report a case of urethral hemangioma in a 60 year old female on account of its rarity.

CASE REPORT

A 60 year old female presented to the gynecology department of our hospital with a mass protruding from the introitus and intermittent urethral bleeding since past 3 months. She was examined and referred to the urology department for further management. Physical examination revealed an erythematous, polypoidal mass surrounding the urethral meatus (Figure 1). The lesion was 3 cm in diameter and firm in consistency and was not friable. Rest of the clinical examination did not reveal any significant findings. Hematological investigations revealed a mild anemia with hemoglobin level of 9.7 gm%. Iron studies and coagulation studies were within normal limits. Ultrasound sonography abdomen and pelvis showed no significant pathology. Urethrocystoscopy was done which showed that the tumor was prolonged until the distal third of the urethra and easily bleeding. The cystoscopy was able to cross the tumor and to explore the posterior urethra, bladder neck and bladder which appeared normal. As it was a distal solitary lesion, decision was made to do a wide excision of the lesion. After the excision, the urethral mucosa was everted and sutured over an indwelling Foleys catheter. The

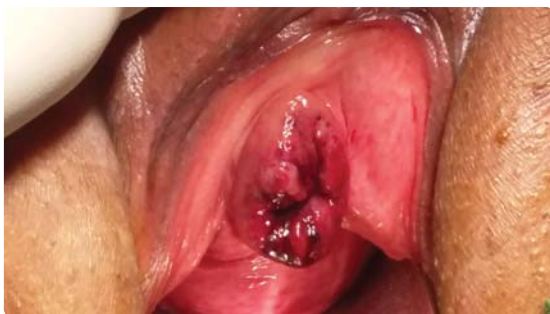

Figure 1: Physical examination showing erythematous, polypoidal mass surrounding the urethral meatus.

catheter was removed after 2 days. Histopathology showed tissue bits lined by transitional epithelium underneath showed a tumor. Tumor composed of variably sized blood-filled vascular spaces lined by flattened endothelial cells separated by thin fibrous septae. Active thrombosis was not seen in the vessels. The final histopathological diagnosis was given cavernous hemangioma of the urethra (Figure 2). The postoperative course was uneventful and till this date there have been no recurrence.

DISCUSSION

Hemangiomas are benign vascular tumors which can occur at any age. They have got a male predominance. They are common in the skin and liver [1]. Hemangiomas of the urinary tract are rare and have been described in the kidney, ureter, bladder, prostate and urethra [2]. Only a handful of cases have been reported in the females [3]. Tumors can be single or multiple. The pathogenesis tumors a believed to be congenital in origin genesis is not clearly understood, two hypotheses clash. Some believe it to be congenital in origin, arising from the embryonic rest of unipotent angioblastic cells that fail to develop into normal blood vessels [4]. Others have implicated that it could also be due to degenerative processes associated with chronic irritative factors .It may coexist with external hemangiomas and congenital disorders like Sturge Weber or Klippel-Trenauny syndrome [5]. Presentation of urethral hemangioma depends on the site and the size of the lesion. Hemangiomas of the anterior urethra may present as urethral bleeding or mass in the introitus in females and lesions located in the proximal urethra usually present as hematuria, urinary retention with blood clots. Our patient presented with mass protruding from

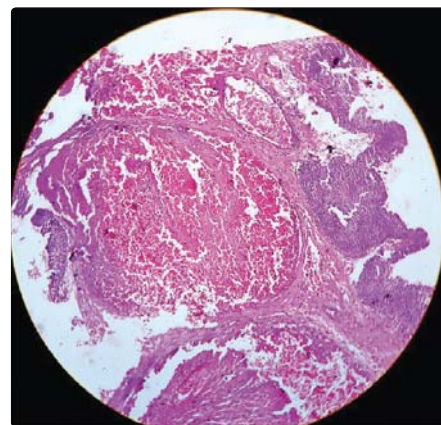


Figure 2: H&E x 100 showing tumor composed of variably sized blood-filled vascular spaces lined by flattened endothelial cells separated by thin fibrous septae.

the introitus and intermittent urethral bleeding. Differential diagnosis includes caruncle, prolapse, squamous cell carcinoma, transitional cell adenocarcinoma, sarcoma and melanoma. Histopathologically, we can easily differentiate these lesions.

Urethrocystoscopy is an excellent diagnostic method that supports in identification of the characteristics, friability, size, location and number of hemangiomas. It also in selection of possible therapeutic and surgical options in different cases [6]. In our case there was an erythematous, polypoidal mass surrounding the urethral meatus. The lesion was 3 cm in diameter and firm in consistency and not friable.

Treatment of urethral hemangioma includes oral steroids for smaller lesions and various endoscopic modalities as transurethral resection and fulguration of base of tumor, laser ablation, selective embolisation, cryotherapy [7,8]. Single localised lesions should undergo wide excision. In our case, the lesion was present at the anterior urethral meatus of urethra, wide surgical excision with fulguration of the base with diathermy was done.

CONCLUSION

Urethral hemangiomas are benign in nature with a tendency to recurrence. Regular follow-up of the patient is always required. It is essential to choose good diagnostic, accurate histopathological and easily available treatment modalities in younger patients to prevent recurrences. Simple transurethral excision of small urethral

hemangiomas may be an effective treatment especially when laser facilities are not available. The cornerstone of right management of urethral hemangiomas is still careful preoperative definition of the extension of the lesion.

REFERENCES

1. De Silva-Gutierrez A, Martinez-Mendez M, Gonzalez-Romo M, Nava-Jacome O, Castillo-Zurita O, Morales-Diaz J, et al. Urethral hemangioma: a case report. *Rev Mex Urol.* 2013; 73: 50-53. <https://goo.gl/e4c9Vt>
2. Tabibian L, Nissen HM. Hemangioma of the urinary tract: review of the literature. *Br J Urol.* 1991; 68: 113-7. <https://goo.gl/8CwXap>
3. Uchida K, Fukuta F, Ando M, Miyake M. Female urethral hemangioma. *J Urol.* 2001; 166: 1008. <https://goo.gl/WURF7u>
4. Tabbian L, Ginsberg DA. Thrombosed urethral hemangioma. *J Urol.* 2003; 170: 1942. <https://goo.gl/Fj9c2A>
5. Rohan VS, Hanji AM, Patel JJ, Tankshali RA. Female urethral hemangioma. *Saudi J Kid Dis Transpl* 2008; 19: 647-648. <https://goo.gl/rSt2DA>
6. Parshad S, Yadav Sp, Arora B. Urethral hemangioma; an unusual case of hematuria. *Urol Int.* 2001; 66:43-45.
7. Ioannis E, Diamantis K, Panagiotis V, Spiridon K. Hemangioma of penile urethra – treatment with simple transurethral excision: a case report. *Cases J.* 2009; 2: 6199. <https://goo.gl/d3aNWD>
8. Khaitan A, Hemal AK. Urethral hemangioma: laser treatment. *Int Urol Nephrol.* 2003; 32: 285-6. <https://goo.gl/JCDBxD>