



International Journal of Case Reports & Short Reviews

Case Report

Small Supernumerary Marker Chromosome: A Case Study from a Speech Language Pathologist's Perspective -

Prianka Evangeline^{1*} and Castroleena J²

¹Lecturer and Clinical Supervisor, MERF Institute of Speech and Hearing (P) Ltd., Tamil Nadu Dr.M.G.R Medical University, Chennai

²BASLP, MERF Institute of Speech and Hearing (P) Ltd., Tamil Nadu Dr.M.G.R Medical University, Chennai

***Address for Correspondence:** Prianka Evangeline, Lecturer and Clinical Supervisor, MERF Institute of Speech and Hearing (P) Ltd., Tamil Nadu Dr.M.G.R Medical University, Chennai, Tel : +919-840-442-235; ORCID: <https://orcid.org/0000-0002-7506-2922>;
E-mail: priankaevangeline@gmail.com

Submitted: 31 December 2019; **Approved:** 18 January 2020; **Published:** 20 January 2020

Cite this article: Evangeline P, Castroleena J. Small Supernumerary Marker Chromosome: A Case Study from a Speech Language Pathologist's Perspective. Int J Case Rep Short Rev. 2020;6(01): 001-003.

Copyright: © 2020 Evangeline P, et al. This is an open access article distributed under the Creative Commons Attribution License, which permits unrestricted use, distribution, and reproduction in any medium, provided the original work is properly cited.



ABSTRACT

Small Supernumerary Marker Chromosome (sSMC) is a rare genetic condition marked by the presence of an extra chromosome to the 46 human chromosomes. This case report describes a 4 year old child with sSMC on the 46th chromosome. The child presented with delayed speech and language development, seizures and mild developmental delay. Speech and Language evaluation was carried out and management options are discussed.

INTRODUCTION

Chromosomes are structures in each of the body's cells that carry the genetic information responsible for the varied functions in the body. There are 23 pairs of chromosomes that is inherited from each parent and numbered from 1 to 23 approximately from smallest to largest. Humans have 46 chromosomes in general. The karyotype of a person with a Small Supernumerary Marker Chromosome (sSMC) shows an addition chromosome to the 46 chromosomes, that is a 47th extra chromosome, known as the marker chromosome [1]. A marker chromosome is defined as a structurally abnormal chromosome that cannot be identified by routine cytogenetics. The risks for phenotypic abnormalities associated with marker chromosome depends on several factors, including inheritance, mode of ascertainment, chromosomal origin, and the morphology, content, and structure of the marker [1,2]. Geneticists code (karyotype) the sSMC in the format: 47XX, + mar (for a female) or 47XY, + mar (for a male) [1]. An sSMC can be derived from any of the 23 different chromosomes - (i.e), chromosomes 1 to 23, an X or a Y chromosome. Most children (70 percent) with a sSMC have parents with no genetic variation. Some inherit their sSMC from one of their parents. If one of the parents have the same sSMC as the child, it has been passed down in the same way as the other chromosomes. This type of sSMC is called familial. In this case the sSMC can be passed on to future children as well. In most cases - but not all - a familial sSMC does not affect the overall health or development of the children. If both parents have no genetic variation, the sSMC has arisen as a one-off event. This event is called de novo [1]. It is also unlikely to happen again in a subsequent pregnancy. sSMC causes partial tris-or tetrasomy. The sSMC frequency in newborn cases is 0.044%, in prenatal cases 0.075%, in mentally retarded cases 0.288%, and in subfertile cases 0.125% [2]. A sSMC can have different effects. Most people 70 percent grow and develop normally and have no health problems but the other 30 percent of population have problems with growth, development, learning or health as a result of their sSMC [1]. Some sSMC lead to specific syndromes [2]. The sSMC can be diagnosed during prenatal screening, when significant dysmorphic facial features are seen and persisting fertility issues with healthy adults [1]. A multitude of different names and abbreviations can be found in the medical literature for sSMC: Supernumerary Marker Chromosome (SMC), Small Accessory Chromosome (SAC), Extra Structurally Abnormal Chromosome (ESAC), extra or additional marker chromosome, bisatellited marker chromosome or Supernumerary Ring Chromosome (SRC) [1].

CASE STUDY

Background information

A 4 year old child was accompanied by his mother to the department of speech and language pathology with the concern of not speaking age adequately. The child communicates his needs and intentions through pointing and single words. The concern was first noticed by his parents at 6 months of age.

Birth history

Prenatal: The mother had gestational diabetes mellitus and maternal hypothyroidism at the first trimester of pregnancy and was under insulin injection and medication respectively. She was under thyronorm tablets.

Perinatal: The child was born out of cesarean delivery, preterm of a week as the child passed meconium in the womb. He was born with immediate birth cry, normal birth weight of 3.4 kg and normal birth color.

Post-natal: The child had poor feeding since birth and developed seizures in 3 hours of life in the form of right lower limb movement associated with upward gaze and was admitted in NICU for 2 days. Other drug given was SYP phenobarbitone 15 mg (5 mg = 20 mg) was given to control seizures for one week. The child underwent surgery for closure of patent ductus arteriosus at the 6 months of age. The child again had seizures at the age of 2 years and has been under medication (Valparin) since.

DEVELOPMENTAL HISTORY

Head control was attained at the age of 3 months. Other milestone were reported to be delayed. Walking without support was attained at the age of 2 years. Speech and language development was reported to be delayed. Cooing, babbling was reported to be delayed. First word was attained at the age of 2 years as reported.

DETAILED EVALUATIONS

Audiological evaluation

Brainstem evoked auditory responses and otoacoustic emission tests done at JIPMER revealed hearing sensitivity within normal limits for both ears.

Previous therapy assessment: Neuro-developmental assessment and occupational therapy assessment was done at CMC, Vellore at the age of 1 years 3 months which reveals that mild developmental delay. The child is attending occupational therapy and physiotherapy in Pondicherry from one and a half years of age and attended speech therapy for 6 months at Boshan Centre in Pondicherry.

Radio-logical evaluation: Brain MRI revealed Microcephaly with simplified gyral pattern in frontal and temporal region.

Chromosomal evaluation: Chromosomal analysis reveals numerical abnormality. The karyotype is mosaic 47XY +mar [80%] 46 XY [20%] that of a male with a marker chromosome (Figure 1).

Detailed evaluation of speech and language: The child was able to maintain eye contact and gaze shift with the communicating partner but had difficulty in maintaining eye contact for more than a minute. On clinical examination Attention Levels and strategies scale by Cooper, Moodley and Reynell reveal that the child achieved an attention level of 3 (corresponding to 2 to 3 years of age) indicating

that the child had single channeled attention but begins to attend to adults. The child was able to maintain dyadic and triadic joint attention. Dyadic attention is a conversation like behaviour that individuals engage in (i.e) takes turn in exchanging facial expressions and noises. Triadic joint attention requires atleast two individuals and each one must be able to understand that both of them are looking at the same object with shared attention. The child had reciprocated smile, and enjoyed playing with peers groups and voluntarily initiates interaction. As reported by the mother the child gets angry if his things are being shared. The child enjoys solo play, parallel play, and associative play. The child was able to look for an object and watches as it moves out of sight, explores objects in different ways like shaking, banging, throwing, as well as functionally. The child knows where things usually belong in the home. Identifies familiar voices by naming the individual. He is able to identify himself in mirror and photographs.

Language comprehension: The child was able to follow two step commands such as (get the pen and give it to akka) when accompanied with gestures, able to recognize family members (mother, father, aunt, uncle, brother, sister, grandmother, grandfather), understands the functional use of common objects such as (comb, tooth brush, plate, spoon, glass, chair, table). The child can understand nouns such as (banana, apple), vegetables (tomato) and animals (cat, dog, crow). The child can understand 'no' and 'bye-bye'. The child understands gestures such as "eat", "drink", "bathe" and "sleep". Means to end relationship (if the switch is turned on, the room will be lit) and object permanence was observed to be present.

Language expression: The child expresses his needs through pointing, gestures and single words. He shows his displeasure through vocalization and crying, amusement through laughing and smiling. Uses voicing to get attention of others. The child can express nouns such as fruits (apple, banana) vegetables (tomato) and all kind of family relationship such as (mother, father, grandmother, grandfather, brother) colors such as (purple, yellow, blue) functional words such as (come, give, leave) and vehicles (car).

Assessment and intervention: Formal assessment was done using CDDC (CommDEALL Developmental Checklist) and LAT (Language Acquisition Tool). CDDC (Karanth, 2007) was used to assess the child in eight domains (i.e) Reception skills, Expression skills, Gross motor skills, Fine motor skills, Emotional skills, Cognitive skills, Activities of daily living and social skills of the child. LAT (Rao, 1986) was used to assess the child's reception and expression skills. The tools revealed that a child has delay of 2.5 years in receptive and expressive skills.

Speech and language intervention plan: The child is undergoing intensive speech and language therapy to improve language comprehension and expression. The language goals for therapy was to improve understanding and verbal expression of lexical categories (common nouns, verbs, adjectives and prepositions), functional communication (verbally expressing daily needs like eating, bathing, help, pain, etc), and responding to simple "wh" question (what, where, and who). The speech related goals for therapy was accurate production and sound discrimination of /p/, /b/, /n/, /m/, /j/, /w/, /d/, /h/.

Occupation therapy to improve pre-linguistic skills like joint attention, eye contact, sitting tolerance and play skills. Intensive (five one hour sessions a week) occupation therapy and speech and language therapy is recommended until age appropriate development milestones are reached.

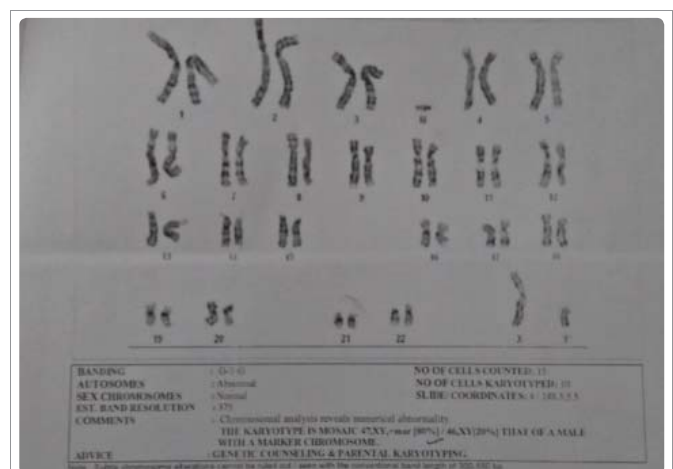


Figure 1: Chromosomal analysis.

REFERENCES

1. Liehr, Small Supernumerary Marker Chromosomes (sSMC): Informational Leaflet by Rare Chromosome Disorder Support Group, Unique 200.
2. Jafari Ghahfarokhi H, Moradi Chaleshtori M, Liehr T, Hashemzadeh Chaleshtori M, Teimori H, Ghasemi Dehkordi P. Small supernumerary marker chromosomes and their correlation with specific syndromes. *Advanced biomedical research*. 2015; 4: 140. <http://bit.ly/38mG6qF>