



International Journal of Case Reports & Short Reviews

Case Report

Laparoscopic Approach to Intestinal Occlusion Due to Incarcerated Femoral Hernia with an Unusual Postoperative Management -

Weber Sanchez Alejandro*

Department of Surgery, Angeles Lomas Hospital, Huixquilucan, Mexico

***Address for Correspondence:** Weber Sanchez Alejandro, Department of Surgery, Angeles Lomas Hospital, Vialidad de la Barranca s/n Office 410Col. Valle de las Palmas, Huixquilucan, Mexico, Tel: +525-552-469-527; ORCID: 0000-0002-0223-9133; E-mail: awebersanchez@gmail.com

Submitted: 29 January 2020; **Approved:** 14 February 2020; **Published:** 17 February 2020

Cite this article: Alejandro WS. Laparoscopic Approach to Intestinal Occlusion Due to Incarcerated Femoral Hernia with an Unusual Postoperative Management. Int J Case Rep Short Rev. 2020;6(2): 004-006.

Copyright: © 2020 Alejandro WS. This is an open access article distributed under the Creative Commons Attribution License, which permits unrestricted use, distribution, and reproduction in any medium, provided the original work is properly cited.

KEYWORDS

Femoral hernia; Incarcerated hernia; Laparoscopy; TAPP repair

INTRODUCTION

Femoral hernias, comprise 2% to 4% of all hernias in the inguinal region, and occur most commonly in women. They present typically with a mass below the level of the *inguinal* ligament. The sac may contain preperitoneal fat, omentum, small bowel, or other structures, and have a high rate of incarceration and strangulation due to the small size of the *hernia* neck orifice, requiring emergency surgery.

We present the case of a 54-year-old female patient with intestinal occlusion due to incarcerated femoral hernia, repaired by laparoscopic approach, that gave the patient the opportunity to attend her daughter's wedding the same day.

CASE PRESENTATION

A female patient without any remarkable personal medical history, was admitted at 11 hours to the emergency department, complaining 1 day prior to admission of painful lump in the left groin, severe suprapubic pain, constipation, vomiting and abdominal distension, which became worse 12 hours before admission. The patient was from another state, and was at the city to attend her daughter's wedding that afternoon.

Physical examination revealed 100 HR, 20 BPM, 125/35 mmHg BP, 36.5°C Temperature and 95% SpO₂. Abdominal distension, mild generalized tenderness, with positive rebound in the left lower quadrant, and a 2X2 cm tender mass, below the level of the left *inguinal* ligament. All laboratory tests were unrevealing, except for mild leukocytosis of 11.5 (WBC) count, 11.5 x 10⁹/L with normal serum biochemistry. Abdominal CT showed a left femoral hernia with small bowel loop imprisoned, and distended loops of small bowel (Figure 1), suggesting an incarcerated femoral hernia.

Although the patient and her family were concerned not only because her medical condition, but also because the circumstance of the imminent wedding, imploring to go to the ceremony, she underwent emergency laparoscopy to perform surgical TAPP repair. A 10 mm umbilical trocar was introduced to the abdominal cavity by a semi open blunt primary access technique, and two additional 5 mm

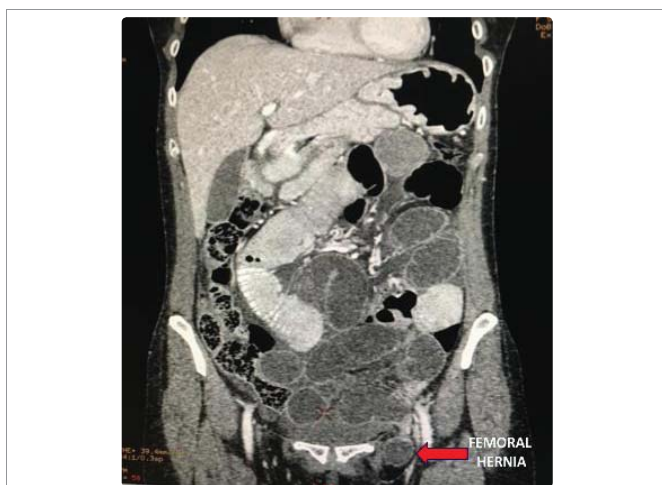

Figure 1: CT showing left femoral hernia and intestinal obstruction.

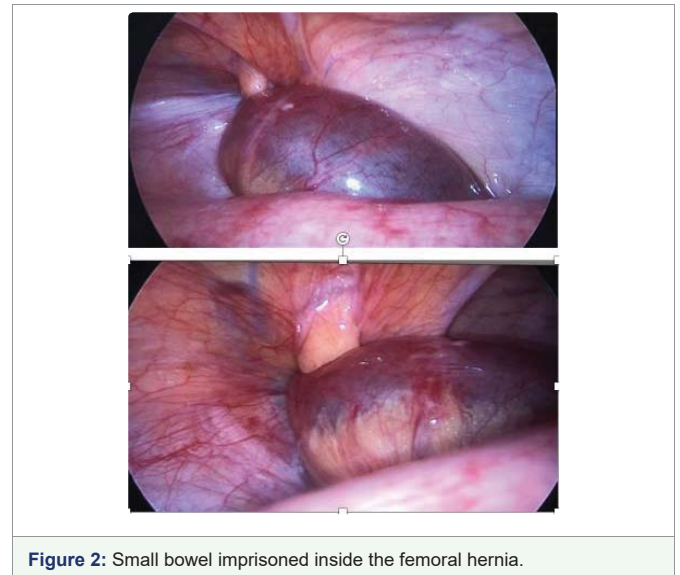


Figure 2: Small bowel imprisoned inside the femoral hernia.

trocars were inserted at the same level of right and left midclavicular line. The diagnostic laparoscopy revealed a small intestine loop imprisoned inside the left femoral orifice with a purplish color suggestive of ischemia (Figure 2).

As the intestinal loop was firmly stuck, to avoid forceful manipulation of the loop, a 1 cm cut was performed at the left edge of the hernia orifice to liberate easily the intestine, reducing it back again into the pelvic cavity. No signs of perforation or contamination were found. The hernia was repaired by TAPP approach with polypropylene mesh placement (Figure 3) and the peritoneum was closed with 00 Stratafix® suture.

When the repair was finished. The released intestinal loop was reviewed. The color and movement were restored without any evidence of vascular compromise, and gas started to pass through the rectum. Intraperitoneal Ropivacaine was infused to get better control of postoperative pain. As soon as she was conscious at the recovery room, she asked permission to assist to the wedding of her daughter. We told her the first hours of her recovery were critical to decide. After two hours at the recovery room, she was taken to her room and kept under close surveillance. Her recovery was uneventful and painless, with normal vital signs, peristalsis, and passing gases through the rectum. Due to her good postoperative evolution, the intestinal transit returned to normal, and her stable clinical condition 6 hours after the procedure, she was authorized to leave the hospital to be present at the ceremony maintaining open communication with us, with instructions to return to the hospital after the religious service to continue her postoperative care (Figure 4).

The patient and her family were very happy to be together at the ceremony celebrating such a meaningful time. She returned to the hospital that night, and was discharged 48 hours later in good conditions.

DISCUSSION

The advantages of laparoscopic hernioplasty, less postoperative pain, fewer postoperative complications, lower recurrence rates, early discharge, and faster return to normal daily activity, have been evident for more than 25 years. Therefore, laparoscopic hernia repair has increased progressively in the world, although in urgent cases its

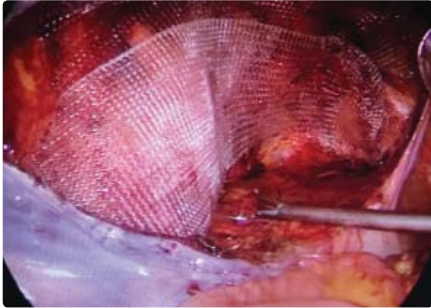


Figure 3: Preperitoneal polypropylene mesh placement.



Figure 4: The patient on her way to the wedding 6 hours after the procedure.

use is still debated by some [1]. But even in these cases of urgency with incarceration or strangulation has demonstrated its usefulness and safety [2-5].

In the case of incarcerated femoral hernia, the viability of the bowel segment is determined on the basis of color, peristalsis, and congestion, and is better observed better from laparoscopic point of view compared with the open approach [6,7]. If laparoscopy reveals an intestinal incarceration in the femoral hernia sac, as in this case, a peritoneal cut to enlarge the orifice is helpful to release the bowel, which is commonly distended and prone to damage when is forceful pulled back with laparoscopic forceps. When there are signs of intestinal ischemia, the intestinal loop may be left in the abdominal cavity to allow its recovery, while the laparoscopic hernia repair is done or decide intestinal resection when viability is in doubt. In the case presented here, the released intestinal loop completely recovered and bowel transit restored during the procedure.

Day surgery for groin hernia repair is safe and effective for most elective patients. However, it is uncommon in complicated cases [8]. For urgent admissions, the hospital stay increases, but laparoscopic

surgery may reduce hospitalization days [9]. Nevertheless it is unusual even for cases of laparoscopic repair, to discharge a patient who had an incarcerated femoral hernia. But there are some exceptional instances like the one that presented by this patient who had the wedding of her daughter that evening. Careful decision must be made to look for security and be compassionate at the same time. Laparoscopic procedure allowed her prompt recovery to permit her to attend to such a significant event in her life and her family, on the same day of her intervention under surveillance, without repercussions, and return to the hospital to continue her postoperative care.

CONCLUSION

In this case of intestinal obstruction due to incarcerated femoral hernia, the TAPP technique allowed the patient to attend her daughter's wedding the same day.

REFERENCES

1. Carter J, Duh QY. Laparoscopic repair of inguinal hernias. *World J Surg.* 2011; 35: 1519-1525. **PubMed:** <https://www.ncbi.nlm.nih.gov/pubmed/21400014>
2. Griffin KJ, Harris S, Tang TY, Skelton N, Reed JB, Harris AM. Incidence of contralateral occult inguinal hernia found at the time of laparoscopic Trans-Abdominal Pre-Peritoneal (TAPP) repair. *Hernia.* 2010; 14: 345-349. **PubMed:** <https://www.ncbi.nlm.nih.gov/pubmed/20358239>
3. McCormack K, Scott NW, Go PM, Ross S, Grant AM, EU Hernia Trialists Collaboration. Laparoscopic techniques versus open techniques for inguinal hernia repair. *Cochrane Database Syst Rev.* 2003; 1. **PubMed:** <https://www.ncbi.nlm.nih.gov/pubmed/12535413>
4. Rosenberg J, Bisgaard T, Kehlet H, Wara P, Asmussen T, Juul P, et al. Danish hernia database recommendations for the management of inguinal and femoral hernia in adults. *Dan Med Bull.* 2011; 58. **PubMed:** <https://www.ncbi.nlm.nih.gov/pubmed/21299930>
5. Yuan Y, Dai W, Chen Z, Zuo J, Tan J, Tan M. Risk factors of postoperative complications after emergency repair of incarcerated groin hernia for adult patients: A retrospective cohort study. *Hernia.* 2018. <http://bit.ly/2HjxNjU>
6. Namba Y, Urushihara T, Nakahara H, Itamoto T. Single-incision totally extraperitoneal hernia repair with intraperitoneal inspection of strangulated femoral hernia at risk for intestinal ischemia after repositioning: A case report. *J Med Case Rep.* 2019; 13: 229. <http://bit.ly/31RgfFi>
7. Chen P, Huang L, Yang W, He D, Liu X, Wang Y, et al. Risk factors for bowel resection among patients with incarcerated groin hernias: A meta-analysis. *Am J Emerg Med.* 2019; 15. **PubMed:** <https://www.ncbi.nlm.nih.gov/pubmed/31836337>
8. Scarfe A, Duncan J, Ma N, Cameron A, Rankin D, Karatassas A, et al. Day case hernia repair: Weak evidence or practice gap? *ANZ J Surg.* 2018; 88: 547-553. **PubMed:** <https://www.ncbi.nlm.nih.gov/pubmed/29573102>
9. Saia M, Mantoan D, Buja A, Bertocello C, Baldovin T, Zanardo C, et al. Increased rate of day surgery use for inguinal and femoral hernia repair in a decade of hospital admissions in the Veneto Region (north-east Italy): A record linkage study. *BMC Health Serv Res.* 2013; 13: 349. **PubMed:** <https://www.ncbi.nlm.nih.gov/pubmed/24028397>