



International Journal of Case Reports & Short Reviews

Case Report

An Unusual Case of Swelling of the Floor of the Mouth Revealing an Epidermoid Cyst: A Case Report -

Sana Mallouk*, Zouhair Najib, Yasser Hammouda, Hafed Radi,
Youssef Oukessou, Sami Rouadi, Reda Abada, Mohamed Mahtar and
Mohamed Roubal

Department of Otorhinolaryngology, Head and Neck Surgery, King Hassan II University Hospital, Casablanca, Morocco

***Address for Correspondence:** Sana Mallouk, Department of Otorhinolaryngology, Head and Neck Surgery, King Hassan II University Hospital, Casablanca, Morocco, Tel: +212-660-729-971; E-mail: sanaa.mallouk@gmail.com

Submitted: 14 August 2020; **Approved:** 30 August 2020; **Published:** 31 August 2020

Cite this article: Mallouk S, Najib Z, Hammouda Y, Oukessou Y, Rouadi S, et al. An Unusual Case of Swelling of the Floor of the Mouth Revealing an Epidermoid Cyst: A Case Report. Int J Case Rep Short Rev. 2020; 6(8): 047-050. <https://dx.doi.org/10.37871/ijcsr.id82>

Copyright: © 2020 Mallouk S, et al. This is an open access article distributed under the Creative Commons Attribution License, which permits unrestricted use, distribution, and reproduction in any medium, provided the original work is properly cited.

ABSTRACT

Introduction: The epidermoid cyst is a benign tumor, included in the group of dermoid cysts. It is a rare tumor; in the floor of the mouth the epidermoid cyst represents 1.6% of cervico-facial dermoid cysts. It can be congenital or acquired.

Case Report: A 20-year-old boy presented to the ENT department for swelling of the floor of the mouth evolving since birth measuring 5cm. Complicated by difficulty in swallowing, chewing and phonation. The treatment consisted of total surgical removal of the cyst by endobuccal excision under general anaesthesia. Histological examination confirmed the diagnosis of epidermal cyst. Following 12 months of monitoring, there was no recurrence and no sequelae.

Conclusion: Epidermoid cyst of the oral cavity is rare, surgical excision is the ideal treatment, because of the risk of recurrence, long-term follow-up is recommended.

INTRODUCTION

Dermoid and epidermoid cysts are a benign disease that may occur in any part of the body. They represent 1.6 to 6.9% of all cysts in the head and neck area [1]. Their presence in the oral cavity is rare because the two entities account only 0.01% of all oral cysts [2]. In the oral cavity, the epidermoid cyst is half as frequent as the dermoid cyst [2]. The diagnosis can be evoked clinically, however the anatomopathological examination is necessary for its confirmation. Epidermoid cysts are characterized by a painless and slow growth. Without treatment, they can grow to a large size that can lead to the life-threatening appearance of dysphagia or even dyspnea [3]. Treatment is surgical, and the approach differs according to the location and size of the lesion.

We report an unusual case of large epidermoid cyst of the floor of the mouth and review the relevant literature.

CASE REPORT

A 20-year-old boy presented to the ENT (Ear, Nose and Throat) consultation department for swelling of the floor of the mouth just below the tongue which has been evolving since birth. Insidious at first, it started as a small pea-sized swelling and gradually increased in size. In addition, the patient presents a difficulties to swallowing, chewing and phonation.

Examination of the oral cavity, revealed a sublingual swelling measuring 5 cm occupying the entire floor of the mouth. It displaced the tongue toward the palate, thus giving the appearance of a "second tongue" (Figure 1). The mobility of the tongue was preserved. The mucosa, sublingual glands and salivary caruncles were normal. Upon bimanual palpation, the mass was soft, depressed, painless, without adhesions. There was no cervical lymphadenopathy and no history of surgery or trauma to the oral cavity.

Ultrasonography showed a cystic formation in the floor of the mouth with a finely echogenic content, well limited, measuring 67x 52 mm (Figure 2), not vascularized with color Doppler, and the rest of the examination is without particularity. However, the Magnetic Resonance Imaging (MRI) was not realized because of financial reasons. Clinical and paraclinical findings suggest a mucoid cyst of the sublingual gland (ranula).

After a preanesthetic check-up, surgical removal was decided under general anesthetic. The intubation was done by orotracheal approach. An incision was made on the ventral side of the tongue measuring 3 cm. After detachment of the mucous membrane, dissection was continued essentially with the finger. Thus, the cyst was completely extracted (Figure 3). The largest diameter of the cyst

was 6 cm. The postoperative recovery period progressed uneventfully. The Histopathological examination revealed a cystic formation lined by keratinized stratified squamous epithelium without any evidence of dermal appendages (Figure 4). So, the diagnosis of epidermoid cyst was made. Following 12 months of monitoring, there was no recurrence and no sequelae.

DISCUSSION

The epidermoid cyst is a benign tumor, included in the group of dermoid cysts. It is a rare tumor; it represents 1.6 to 6.9% of all cysts in the head and neck area [1]. However, in the floor of the mouth the epidermoid cyst represents 1.6% of cervico-facial dermoid cysts [4]. However, other locations have been reported in the literature, namely the tongue, lips and oral mucosa [5]. Concerning the physiopathology of the epidermoid cyst of the oral floor, there are two theories in function if the cyst is congenital or acquired. The congenital cyst is the result of trapped ectodermal tissue of the first and second branchial

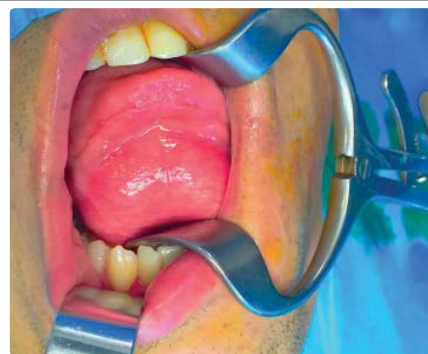

Figure 1: Examination of the oral cavity, revealed a sublingual swelling measuring 5 cm occupying the entire floor of the mouth.

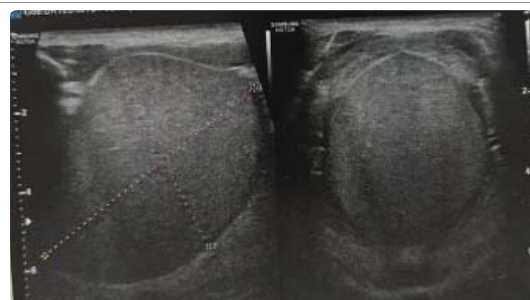


Figure 2: Ultrasonography showed a cystic formation in the floor of the mouth with a finely echogenic content, well limited, measuring 67x 52 mm.

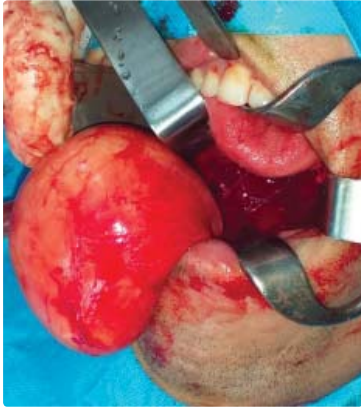

Figure 3: Surgical excision of the totality of the cyst.

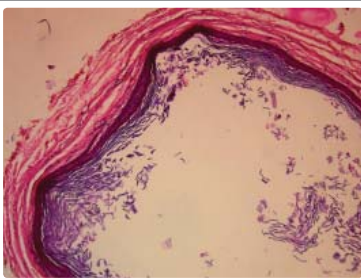


Figure 4: The Histopathological examination revealed a cystic formation lined by keratinized stratified squamous epithelium without any evidence of dermal appendages.

arches, or it is a variant of the thyroglossal duct cyst with predominant ectodermal elements [6]. Acquired form is the result of implantation of the epithelial cells of the injury or surgery [7]. The incidence of epidermoid cysts is highest between the ages of 15 and 35, with a male predilection [8]. A recent study reported one case in a 6-year-old girl [9]. Our patient is a 20-year-old boy. This tumor is characterized by an often slow, painless evolution that can vary from a few months to several years with a gradual increase in size [6,5,9]. Usually the size of this cyst is between 1 and 5 cm and occasionally it can be larger [10]. In our observation, the tumor has evolved from toddlerhood to a size of 67x 52 mm. Usually, patients consult for painless swelling of the floor of the mouth. Signs of complications such as dysphagia, dysphonia and dyspnea are rare and take a long time to appear [11]. In our observation, in addition to the increase in the size of the mass, the patient presented a gene to swallowing, chewing and phonation which required emergency therapy.

Paraclinical examinations such as ultrasonography, Computed Tomography (CT) scans and Magnetic Resonance Imaging (MRI) play an essential role in the anatomical localization of the mass in the floor of the mouth to guide the surgical approach, as well as eliminating other differential diagnoses [12]. MRI is the examination of choice for the diagnosis of cystic mass and the visualization of oral floor anatomy thanks to its excellent soft-tissue contrast [12,13]. The anatomical classification divides the epidermoid cysts on the floor of the mouth into two groups: the first group develops above the mylohyoid muscle, responsible for a displacement of the tongue towards the palate and difficulties in mastication, speech or even a respiratory gene, and the second group develops below the

mylohyoid muscle responsible for a sub-mental or sub-mandibular lesion [12,13]. Dermoid cysts of the floor of the mouth should be differentiated from other midline swellings of the oral cavity such as Ranulas, Thyroglossal duct cysts, Branchial cleft cysts and oral abscess [12]. Because of lack of financial means, our patient only had a cervical ultrasonography which oriented the diagnosis towards rannula of the oral floor.

However, the specific histological type can only be confirmed by histopathological examination after surgical excision. There are three histological variants, namely: Dermoid cyst, epidermoid and teratoid. The cavity of the dermoid cyst is lined by a keratinized epithelium and has superficial skin appendages. However, a simple squamous epithelium without skin appendages lines the epidermal cyst. The teratoid cyst consists of tissue from all three germinal layers [14].

Total surgical excision is a treatment of choice for epidermoid cyst which can be performed by the intra-oral or extra-oral approach or a combination of both depending on the size and location of the cyst [15]. Generally, the extra-oral approach is performed in case of a large cyst [16]. In our observation, the excision was performed by intraoral approach under general anesthesia. The prognosis is good after an absolute surgical excision.

Recurrences are unusual and the risk of malignant transformation is described in the literature but remains rare [17]. However, long-term follow-up is recommended.

CONCLUSION

- Epidermoid cyst of the floor of the mouth is a benign tumour which can cause dysphonia, dysphagia or even dyspnea in the case of a large lesion.
- Clinical and paraclinical data guide the diagnosis but its confirmation is made by anatomopathological examination of the excisional specimen.
- Diagnostic imaging help in the correct diagnosis, but its confirmation is made by anatomopathological examination of the excisional specimen.
- Surgical excision is the ideal treatment.
- Although the risk of recurrence and malignant transformation is low, long-term follow-up is recommended.

REFERENCES

1. Jhams BC, Duraes GV, Jhams AC, Santos CR. Epidermoid cyst of the floor of the mouth: A case report. *J Can Dent Asso.* 2007; 73: 525-528. <https://bit.ly/2YKkc9y>
2. Yilmaz I, Yilmazer C, Yavuz H, Bal N, Ozluoglu LN. Giant sublingual epidermoid cyst: A report of two cases. *J Laryngol Otol.* 2006; 120: 19. DOI: 10.1017/s0022215106009194
3. Park Sw, Lee Jj, Chae Sa, Yoo Bh, Kim Gj, Lee Sy. Congenital epidermoid cyst of the oral cavity: Prenatal diagnosis by sonography. *Clin Exp Otorhinolaryngol.* 2013; 6: 191-193. DOI: 10.3342/ceo.2013.6.3.191
4. Ghorbel A, Moalla J, Mnejja M, Bouayed W, Dhoubi M, Chakroun A. Dermoid cyst of the floor of the mouth. *J Tun ORL.* 2007; 18: 58-60.
5. Correa Msnp, Fonoff Rdn, Ruschel Hc, Parizotto Spcdol, Correa Fnp. Lingual epidermoid cyst: Case report in an infant. *Pediat Dentist.* 2003; 25: 591-595. <https://bit.ly/3b9BB5c>
6. Kandogan T, Koç M, Vardar E, Selek E, Sezgin O. Sublingual epidermoid cyst: A case report. *J Med Case Rep* 2007; 1: 87. DOI: 10.1186/1757-1626-0002-0000008848

7. Yilmaz I, Yilmazer C, Yavuz H, Bal N, Ozluo- Glu Ln. Giant sublingual epidermoid cyst: A report of two cases. *J Laryng & Otol.* 2005; 19. DOI:10.1017/S0022215106009194
8. Hemaraju N, Nanda SK, Medikeri SB. Sub-lingual dermoid cyst. *Indian J Otolaryngol Head Neck Surg.* 2004; 56: 218-220. DOI: 10.1007/BF02974355
9. Kumari N, Kumar A, Kumar A. Sublingual epidermoid cyst in a young girl. *Journal of Pediatric Surgery Case Reports.* 2018; 30: 74-76.
10. Kang SG, Kim CH, Cho HK, Park MY, Lee YJ, Cho MK. Two cases of giant epidermal cyst occurring in the neck. *Ann Dermatol.* 2011; 23: 135-138. DOI: 10.5021/ad.2011.23.S1.S135
11. Marino R, Pertenero M, Famillari U, Gon- Dolfo S. Dermoid cyst of the floor of the mouth: A case report. *J Clin Cas Rep.* 2012; 2: 150.
12. Giarraputo L, Savastano S, D'Amore E, Baciliero U. Dermoid cyst of the floor of the mouth: Diagnostic Imaging Findings. *Cureus.* 2018. <https://bit.ly/3hMoycv>
13. La'Porte SJ, Juttla JK, Lingam RK. Imaging the floor of the mouth and the sublingual space. *Radiographics.* 2011; 31: 1215-1230. <https://bit.ly/3hJPXMe>
14. Vargas Fernandez JL, Lorenzo Rojas J, Aneiros Fernandez J, Sainz Quevedo M. Dermoid cyst of the floor of the mouth. *Acta Otor-rinolaringol Esp.* 2007; 58: 31-33. <https://bit.ly/3hJQtKa>
15. Tsirevelou P, Papamantios M, Chlopsidis P, Zourou I, Skoulakis C. Epidermoid cyst of the floor of the mouth: Two case reports. *Cases J.* 2009; 2: 9360. DOI: 10.1186/1757-1626-2-9360
16. Yavuz Findik , Olgun Topal , Mehmet Fatih Senturk, Timucin Baykul. Extraoral approach of the surgical treatment of sublingual epidermoid cyst: A case report. *J Pak Med Assoc.* 2017; 67: 796-798. <https://bit.ly/34OSPnd>
17. Devine Dc, Jones JC. Carcinomatous trans- formation of a sublingual dermoid cyst: A case report. *Int Journ of Oral and Maxillofacial Surgery.* 2000; 29: 126-127. <https://bit.ly/2QDHzs5>