



# International Journal of Clinical Endocrinology

## Case Report

# A Rare Case of Gastric Heterotopic Pancreas with Cholecystoduodenal Fistula – A Case Report - 6

**Lalit Kumar Bansal<sup>1\*</sup>, Stuti Gupta<sup>2</sup>, Annu Singhal<sup>1</sup> and Arvind Ahuja<sup>1</sup>**

<sup>1</sup>ABVIMS and Dr. Ram Manohar Lohia Hospital and Post Graduate, Institute of Medical Education and Research, New Delhi

<sup>2</sup>All India institute of medical sciences, New Delhi

**\*Address for Correspondence:** Lalit Kumar Bansal, ABVIMS and Dr. Ram Manohar Lohia Hospital and Post Graduate, Institute of Medical Education and Research, New Delhi, Tel: 8130368883; E-mail: dr.lkbansal@gmail.com

**Submitted:** 23 March 2020; **Approved:** 04 May 2020; **Published:** 06 May 2020

**Cite this article:** Bansal LK, Gupta S, Singhal A, Ahuja A. A Rare Case of Gastric Heterotopic Pancreas with Cholecystoduodenal Fistula – A Case Report. Int J Clin Endocrinol. 2020;4(1): 001-003.

**Copyright:** © 2020 Bansal LK, et al. This is an open access article distributed under the Creative Commons Attribution License, which permits unrestricted use, distribution, and reproduction in any medium, provided the original work is properly cited.

## ABSTRACT

Ectopic pancreatic tissue (or heterotopic pancreas) is the pancreatic tissue that lies outside and separates to the pancreatic gland and lacks anatomical or vascular connections with the original pancreas. It is a congenital anomaly due to aberration in its development. Mostly asymptomatic, it can present with chronic abdominal pain, gastrointestinal bleeding, abscesses, obstruction chronic pancreatitis, and malignancy. Its association with Cholecystoduodenal fistula has not been described till yet. Here, we present 35 yr. lady, with Heterotopic Pancreas, who presented with Gastric Outlet Obstruction with Cholecystoduodenal fistula. This condition is rare and difficult to diagnose. Also, malignancy should be rule out as the management is different in both of these conditions.

**Keywords:** Heterotopic pancreas; intestinal obstruction; Cholecystoduodenal fistula

## INTRODUCTION

Heterotopic Pancreas (HP) is the pancreatic tissue that lacks anatomical or vascular connections with the original pancreas and lies outside and separates from it [1]. Most patients are asymptomatic and found incidentally during endoscopy, surgery, or autopsy. It is found in approximately 5% of people on autopsy [2]. Heterotopic tissue can be frequently found throughout the upper gastrointestinal tract with most commonly located within the stomach, duodenum, and jejunum. It usually presents in the fifth to sixth decade and is three times more likely to be in men [3]. In the stomach, it can present with chronic abdominal pain, gastrointestinal bleeding, abscesses, obstruction, and chronic pancreatitis [2,4].

Heterotopic pancreas is mostly asymptomatic, and malignant transformation is rare [5]. On presentation, it possesses a diagnostic dilemma to clinicians because of little help comes from endoscopy and imaging. Surgical exploration [6] is the only option, and diagnosis mostly made on histopathological examination. Although open surgery is preferred, recently laparoscopic and endoscopically have also been used.

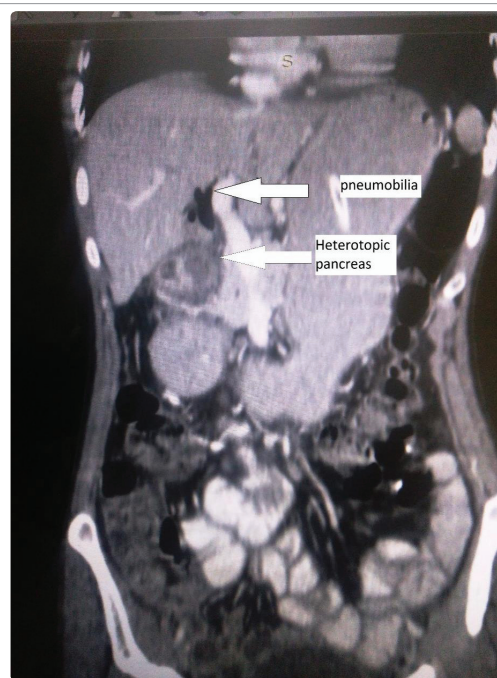
Cholecystoduodenal fistula is the fistulous connection between gallbladder and duodenum, which is the most common type of enterobiliary fistulation. It occurs spontaneously and is a rare complication of an untreated gallstone and inflammatory process.

## CASE REPORT

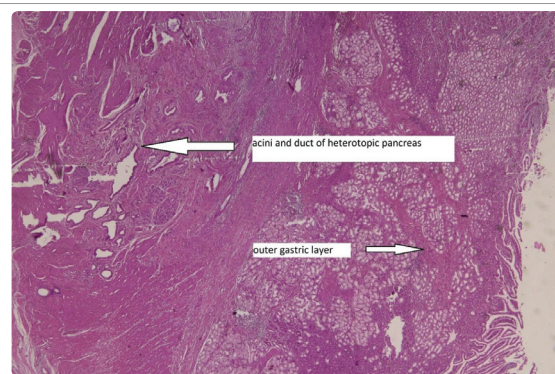
A 35-year-old female presented to surgery outpatient clinic with a 2-month history of pain and fullness of the upper abdomen, postprandial vomiting, and significant weight loss. Physical examination revealed epigastric fullness due to a distended stomach. Abdominal ultrasonography revealed cholelithiasis with oedematous and thickened wall gall bladder. CECT showed a grossly distended stomach with asymmetrically enhancing mural thickening of 13mm involving the first and second part of the duodenum, causing significant luminal narrowing. The gall bladder was seen to be abutting the duodenum and had a thick oedematous wall with pneumobilia (Figure 1). Upper GI endoscopy revealed thickened pylorus with a ulcero-proliferative lesion in the first part of the duodenum. Tissue biopsy was unremarkable.

She underwent exploratory laparotomy, which revealed the first part of the duodenum to be thick-walled and gallbladder attached to it through the fistula (Figure 1). Multiple calculi were palpable in GB. Thickening was extending towards pylorus, and slight deformity of the duodenum was seen. The rest of the visualized bowel and viscera was normal. Cholecystoduodenal fistula was excised, and cholecystectomy was done. Fistulous tract with part of duodenum and cholecystectomy specimens were sent for frozen sections, which were negative for

malignancy. Distal gastrectomy, including duodenal thickened mass with Roux-en-Y reconstruction was done. Histopathological examination of pyloric end revealed focal mucosal ulceration replaced by granulation tissue. Muscularis propria showed irregularly dilated ducts and islands of normal pancreatic acini and islets of Langerhans. Sections from gall bladder showed intestinal metaplasia, pseudo pyloric metaplasia, and low-grade dysplasia (Figure 2). The patient had an uneventful post-operative recovery.



**Figure 1:** CT scan image showing heterotopic pancreas with pneumobilia.



**Figure 2:** Histopathology showing outer gastric layer with pancreatic duct and acini.

## DISCUSSION

Jean-Schultz firstly reported a heterotopic pancreas as a congenital abnormality [1]. During embryological development, the pancreas is derived from endodermal invaginations of the primitive duodenal wall. The dorsal diverticulum becomes body and tail, and the ventral portion becomes head of the pancreas. Sometimes, one or more of these invaginations remain in the bowel wall and incorporates in the upper gastrointestinal tract. HP is believed to arise from the fragments of the pancreas that were separated from the main body and deposited in the ectopic sites [7]. Another, the metaplasia theory states that the heterotopic pancreas arises from areas of pancreatic metaplasia of endoderm, which migrate to the submucosa during embryogenesis [7]. The heterotopic pancreas is usually located in the submucosa. Therefore, it is difficult to diagnose on endoscopic-biopsy. It makes endoscopic ultrasonography useful in the diagnosis, and EUS guided FNAC as the most sensitive and specific diagnostic modality [8].

The heterotopic pancreas is histologically divided into three types, according to von Heinrich's classification [1]. Type I had ducts, acini, and islets of Langerhans cells, similar to a healthy pancreas. Type II had ducts only, and Type III showed acini and type IV islets. The heterotopic pancreas is mostly asymptomatic. When present, symptoms depend on anatomical location and size of the lesion. The heterotopic pancreas can present with abdominal pain and distension. It can also manifest as rare diseases of the pancreas, including pancreatitis, islet cell tumor, pancreatic carcinoma, and pancreatic cyst [4].

Heterotopic Pancreatic (HP) masses and Stromal Tumors (STs) are common gastric submucosa tumors. HP masses are typically found in autopsy or surgery, during which the frequency is approximately 0.2 to 0.25% [1,2]. Approximately 10-15 per million people worldwide are diagnosed with gastrointestinal STs each year, with most of these tumors located in the stomach [3]. Both the management and prognosis of these two tumors are different [4,6].

Stromal tumors are aggressive tumors with a potential tendency for malignancy. They require resection once detected, while HP is generally asymptomatic, and only a few patients need to be treated because of complications. Because of the above, an accurate preoperative diagnosis of stromal tumors is critical. HP has characteristic CT features for differentiating it from stromal tumors in the stomach [9].

HP is more commonly symptomatic in the 4th to 5th decade, but it can be symptomatic in the paediatric population also. The presence of a heterotopic pancreas should be considered in paediatric patients with gastrointestinal symptoms of unclear origin, especially in the setting of acute presentation. The resection of heterotopic tissue is the procedure of choice to diagnose the condition and to avoid future complications [10].

In our case, a 35-year lady presented with features of gastric outlet obstruction. Imaging shows thickened pylorus and pneumobilia. On histopathology, the diagnosis of the heterotopic pancreas was made. It shows low-grade dysplasia and intestinal metaplasia. HP usually associated with pancreatitis, pseudocyst formation, malignant

degeneration, gastrointestinal bleeding, bowel obstruction, and intussusception. But in our case, it was presented with gastric outlet obstruction and Cholecystoduodenal fistula, which was later diagnosed as a heterotopic pancreas on histopathological examination.

## CONCLUSION

Heterotopic pancreas is a congenital anomaly posing a challenge to diagnose on imaging and endoscopy; instead, most cases are identified at surgery or autopsy. To date, there have been no reports describing heterotopic pancreas with Cholecystoduodenal fistulas.

## METHODS

I declare that consent has been obtained from the patient after a full explanation of the purpose and nature of all procedures used.

I also declare that approval is not required in our study as the patient is not harmed during all procedures.

## REFERENCES

1. Jiang LX, Xu J, Wang XW, Zhou FR, Gao W, Yu GH, et al. Gastric outlet obstruction caused by the heterotopic pancreas: A case report and a quick review. *World J Gastroenterol* 2008; 14: 6757-6759. **PubMed:** <https://www.ncbi.nlm.nih.gov/pubmed/19034986/>
2. Wei R, Wang QB, Chen QH, Liu JS, Zhang B. Upper gastrointestinal tract heterotopic pancreas: Findings from CT and endoscopic imaging with histopathologic correlation. *Clin Imaging*. 2011; 35: 353-359. **PubMed:** <https://www.ncbi.nlm.nih.gov/pubmed/21872124>
3. Mulholland KC, Wallace WD, Epanomeritakis E, Hall SR. Pseudocyst formation in gastric ectopic pancreas. *JOP*. 2004; 5: 498-501. **PubMed:** <https://www.ncbi.nlm.nih.gov/pubmed/15536290>
4. Sandrasegaran K, Maglinte DD, Cummings OW. Heterotopic pancreas: Presentation as jejunal tumor. *AJR Am J Roentgenol*. 2006; 187: W607-W609. **PubMed:** <https://www.ncbi.nlm.nih.gov/pubmed/17114513>
5. Sadeghi NR, Godambe A, Shienbaum AJ, Alloy A. Premalignant gastric heterotopic pancreas *Gastroenterol Hepatol*. 2008; 4: 218-221. **PubMed:** <https://www.ncbi.nlm.nih.gov/pubmed/21904502/>
6. Ayantunde AA, Pinder E, Heath DI. Symptomatic pyloric pancreatic heterotopia: report of three cases and review of the literature. *Med Sci Monit*. 2006; 12: CS49-CS52. **PubMed:** <https://www.ncbi.nlm.nih.gov/pubmed/16733487>
7. Azam M, Taj A, Haider N, Amer W, Imran M. Role of upper gastrointestinal endoscopy in Patients with Iron deficiency Anemia. *Pak Postgrad Med J*. 2000; 11: 12-15.
8. Christodoulidis G, Zacharoulis D, Barbanis S, Katsogridakis E, Hatzitheofilou K. Heterotopic pancreas in the stomach: A case report and literature review. *World J Gastroenterol* 2007; 13: 6098-6100. **PubMed:** <https://www.ncbi.nlm.nih.gov/pubmed/18023108/>
9. Li-ming Li, Lei-yu Feng, Xiao-Hua Chen, Pan Liang, Jing Li, Jian-bo Gastric heterotopic pancreas, and stromal tumors smaller than 3 cm in diameter: clinical and computed tomography findings. *Cancer Imaging*. 2018; 18: 26. **PubMed:** <https://www.ncbi.nlm.nih.gov/pubmed/30086800>
10. Giorgio Persano, Noemi Cantone, Elisa Pani, Enrico Ciardini, Bruno Nocchioli. Heterotopic pancreas in the gastrointestinal tract in children: a single-center experience and a review of the literature. *Ital J Pediatr*. 2019; 45: 142. **PubMed:** <https://www.ncbi.nlm.nih.gov/pubmed/31706342>