



# International Journal of Reproductive Medicine & Gynecology

## Case Report

# Laparoscopic Management of Cornual Ectopic Pregnancy - ②

Irati Telleria, Mikel Gorostidi\*, Maialen Olazabal, Marta Urbistondo, Ibon Jaunarena, Arantxa Lekuona

*Department of Obstetrics and Gynaecology, University Hospital Donostia, San Sebastián, Spain*

\***Address for Correspondence:** Mikel Gorostidi Pulgar, Department of Obstetrics and Gynaecology, University Hospital Donostia, P. Beguiristain s/n, 20014 San Sebastián, Spain, Tel: +34943007000; E-mail: mgorostidi@sego.es

**Submitted:** 08 September 2016; **Approved:** 30 January 2017; **Published:** 07 February 2017

**Citation this article:** Telleria I, Gorostidi M, Olazabal M, Urbistondo M, Jaunarena I, et al. Laparoscopic Management of Cornual Ectopic Pregnancy. SRL Reprod Med Gynecol. 2017;3(1): 001-003.

**Copyright:** © 2017 Telleria I, et al. This is an open access article distributed under the Creative Commons Attribution License, which permits unrestricted use, distribution, and reproduction in any medium, provided the original work is properly cited.

**ABSTRACT**

In this manuscript we show the successful laparoscopic treatment of a ruptured cornual ectopic pregnancy. In many settings this condition is treated by open approach due to the advanced skills required to control bleeding. This is a case report with the aim of showing images of the procedure, how to easily prevent bleeding and the management of it.

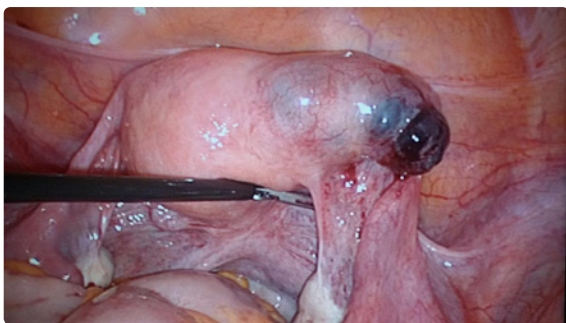
**INTRODUCTION**

Cornual Ectopic Pregnancy (CEP) is defined as a pregnancy in which implantation occurs in the proximal portion of the fallopian tube. Most of the authors use the terms “cornual” and “interstitial” interchangeably. The incidence of CEP is low, account for 2-4% of ectopic pregnancies [1-14]. In general, risk factors for CEP are similar to those for ectopic pregnancy, and ipsilateral salpingectomy is a risk factor unique for cornual pregnancy [1,4,5,7,11,13]. It’s one of the most difficult complicated gestations to diagnose and treat due to the risk of massive bleeding (mortality rate of 2-2.5%) [2-8,11,12]. Once diagnosis is made, both medical and surgical treatments have been reported [1,4,12]. Traditionally, treatment of CEP has been laparotomy with cornual resection or hysterectomy [1-3,8-14]. In recent years, laparoscopic management is becoming more common thanks to equipment improvement and trained surgeons.

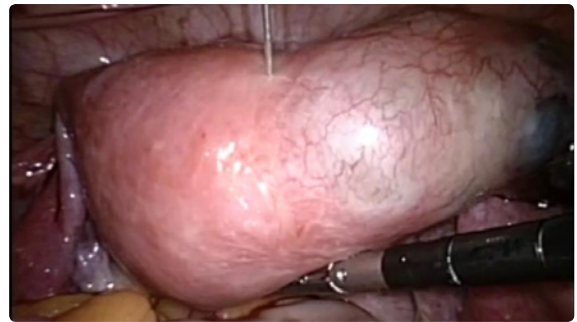**CASE**

A 35 years-old woman was seen at emergency room of a private institution in May 2016 complaining of abdominal pain. A massive hemoperitoneum and probable right anexial involvement that suggested active bleeding was diagnosed. Laparoscopic surgery was performed with the diagnosis of right cornual ruptured pregnancy. After hemoperitoneum aspiration and patient’s stabilisation, patient was transferred to our center (Hospital Universitario Donostia, OSI Donostialdea, Spain), very close and quickly accessible, due to better therapeutic possibilities for better outcomes. Patient was immediately admitted in our centre for surgery without delay. Ultrasound performance visualised an irregular formation of 25 x 30 mms with 5 mms. Gestational sac and embryo beat positive inside. B-hCG levels were very low (21.1 U/ ml).

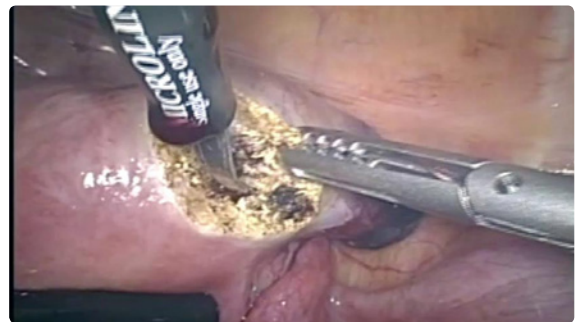Being the woman hemodynamically stable the case was resolved successfully by laparoscopic surgery. Expert laparoscopists performed right cornual wedge resection. Surgery lasted 190 minutes. Blood loss during surgery was negligible after vaginal misoprostol administration and diluted adrenalin intramyometrial injection (Haemoglobin 8.8g/ dl at admitting and 9.3g/ dl at discharge after transfusion of 3 blood pouches at surgery-room) (Figures 1-4) and the cornual defect was



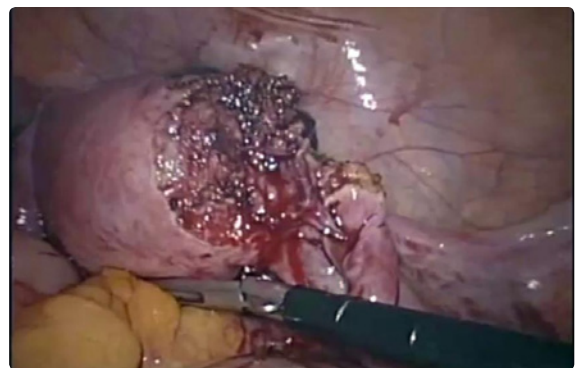**Figure 1:** Right rupture cornual pregnancy, laparoscopic view.



**Figure 2:** Intramyometrial injection of diluted vasoconstrictor.



**Figure 3:** Right cornual wedge resection by scissors and forceps.



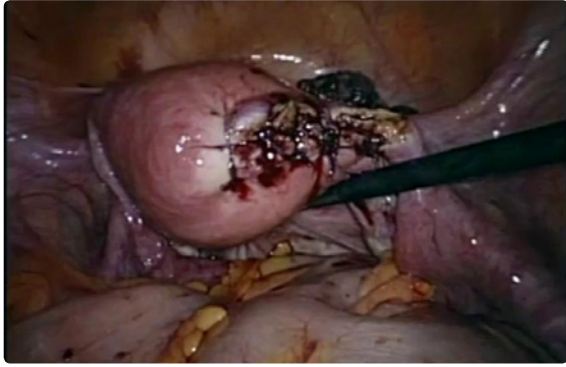
**Figure 4:** Cornuectomy.

closed by interrupted sutures (absorbable suture, poliglicolic 2-0, Vicryl). (Figures 5,6). Then right salpingectomy was done. The patient was discharged 2 days after surgery.

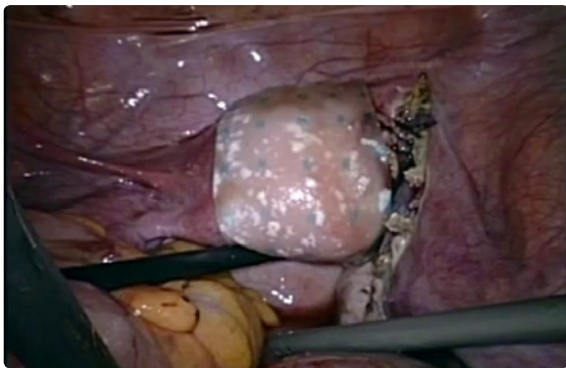
**DISCUSSION**

CEP is a rare form of ectopic pregnancy and remains one of the most difficult ectopic pregnancies to diagnose and treat [1,2,6].

Regarding surgical treatment, main concerns are haemorrhage



**Figure 5:** Final result of surgery. Interrupted sutures.



**Figure 6:** Hemostatic and anti adhesion barrier left in the surgical site.

and the need for adequate cornual reconstruction to prevent uterine rupture in future subsequent pregnancy, which necessitate advanced laparoscopic skills and technique [3,5,8,11]. To minimize blood loss, laparoscopic procedures can be used by different techniques. Uterotonic vaginal misoprostol and injection of vasoconstrictors previous to surgery can be used. Diluted intramyometrial vasopressin injection is the most well-known and preferable procedure [4,7,14] obtaining a fast whitening of the tissue and allowing a non bleeding surgery effectively. If vasopressin is not available, other different vasoconstrictor even adrenalin can be used (It is worse tolerated than other drugs, and can only be used with patient strict monitoring, due to the risk of tachycardia inclusive cardiac arrest). Some studies [15], analysed the effect of vaginal misoprostol on the reduction of uterine bleeding in myomectomies. There is one study establishing that a single dose of misoprostol resulted in a statistically significant reduction in intraoperative blood loss and reduced need for postoperative blood transfusion when compared to placebo. It's not as effective as other methods, but it's easy, quick and cheap.

Other laparoscopists have used other methods, like ligation of ascending branches of the uterine vessels, uterine devascularisation, apposition of fibrin glue or tourniquets applied around the cornual mass or through the avascular area of the broad ligament [4,7,9,11]. These methods require a high level of laparoscopic skills [9].

In the last years the use of more conservative surgical alternatives, such as cornuostomy rather than cornuectomy are introduced to better preserve of uterine integrity for future fertility [4,6,8,12,13]. Integrity of myometrium after conservative treatments is unclear;

patients must be counselled carefully about the risk of uterine rupture in subsequent pregnancy. To prevent this severe complication, normal uterine tissue must be preserved avoiding tissue damage by electro surgery and by minimal excision of cornual tissue [5,8]. Suture closure of the cornual defect remains the most appropriate method for the achievement of haemostasis and may also minimize the risk of uterine rupture in subsequent pregnancy [8,9,11,12].

Close antenatal follow-up of patient with history of CEP is mandatory. The incidence of recurrent CEP is unknown [1,12]. Transvaginal ultrasound should be performed 5-6 weeks after the last menstrual period to ensure the correct implantation of the subsequent gestation [12]. Typically, elective caesarean section should be planned to reduce the risk of rupture in labour [6,7,8,12].

In conclusion, laparoscopic management of CEP with minimum blood loss is safe and feasible by trained surgeons.

## REFERENCES

1. Siow A, Ng S. Laparoscopic management of 4 cases of recurrent cornual ectopic pregnancy and review of literature. *J Minim Invasive Gynecol.* 2011; 18: 296-302.
2. Ross R, Lindheim SR, Olive DL, Pritts EA. Cornual gestation: a systematic literature review and two case reports of a novel treatment regimen. *J Minim Invasive Gynecol.* 2006; 13: 74-78.
3. Mahmoud MS. Technique for the laparoscopic management of a cornual ectopic pregnancy. *J Minim Invasive Gynecol.* 2016; 23: 300.
4. Pluchino N, Ninni F, Angioni S, Carmignani A, Genazzani AR, Cela V. Spontaneous cornual pregnancy after homolateral salpingectomy for an earlier tubal pregnancy: a case report and literature review. *J Minim Invasive Gynecol.* 2009; 16: 208-211.
5. Moon HS, Kim SG, Park GS, Choi JK, Koo JS, Joo BS. Efficacy of bleeding control using a large amount of highly diluted vasopressin in laparoscopic treatment for interstitial pregnancy. *Am J Obstet Gynecol.* 2010; 203: 30.e1-6.
6. Tinelli A, Malvasi A, Pellegrino M, Pontrelli G, Martulli B, Tsin DA. Laparoscopic management of cornual pregnancies: a report of three cases. *Eur J Obstet Gynecol Reprod Biol.* 2010; 151: 199-202.
7. Lau s, Tulandi T. Conservative medical and surgical management of interstitial ectopic pregnancy. *Fertil Steril.* 1999; 72: 207-215.
8. Ng S, Hamontri S, Chua I, Chern B, Siow A. Laparoscopic management of 53 cases of cornual ectopic pregnancy. *Fertil Steril.* 2009; 92: 448-452.
9. Choi YS, Eun DS, Choi J, Shin KS, Choi JH, Park HD. Laparoscopic cornuotomy using a temporary tourniquet suture and diluted vasopressin injection in interstitial pregnancy. *Fertil Steril.* 2009; 91: 1933-1937.
10. Lazard A, Poizac S, Courbiere B, Cravello L, Gamera M, Agostini A. Cornual resection for interstitial pregnancy by laparoendoscopic single-site surgery. *Fertil Steril.* 2011; 95: 2432.e5-8.
11. Hwang JH, Lee JK, Lee NW, Lee KW. Open cornual resection versus laparoscopic cornual resection in patients with interstitial ectopic pregnancies. *Eur J Obstet Gynecol Reprod Biol.* 2011; 156: 78-82.
12. Moawad NS, Mahajan ST, Moniz MH, Taylor SE, Hurd WW. Current diagnosis and treatment of interstitial pregnancy. *Am J Obstet Gynecol.* 2010; 202: 15-29.
13. Soriano D, Vicus D, Mashlach R, Schiff E, Seidman D, Goldenberg M.. Laparoscopic treatment of cornual pregnancy: a series of 20 consecutive cases. *Fertil Steril.* 2008; 90: 839-843.
14. Nirgianakis K, Papadia A, Grandi G, McKinnon B, Bolla D, Mueller MD. Laparoscopic management of ectopic pregnancies: a comparison between interstitial and "more distal" tubal pregnancies. *Arch Gynecol Obstet.* 2016; 295: 95-101.
15. Celik, Sapmaz. Misoprostol use in abdominal myomectomy. *Fertil Steril.* 2003; 79: 1207-1210.