



Scientific Journal of Neurology & Neurosurgery

Case Report

Intracranial Immature Teratoma of the Lateral Ventricle: A Case Report - ②

Keyvan Mostofi* and Marie Josephine WANDJI

Centre Clinique De Soyaux Department of Neurosurgery Chemin De Fregeneuil, France

***Address for Correspondence:** Keyvan Mostofi, Hopital Lorrain, Department of Neurosurgery, St Joseph, France, E-mail: keyvan.mostofi@yahoo.fr

Submitted: 19 November 2015; Approved: 22 December 2015; Published: 31 December 2015

Citation this article: Mostofi K, WANDJI MJ. Intracranial Immature Teratoma of the Lateral Ventricle: A Case Report. Scientific Journal of Neurology & Neurosurgery. 2015;1(1): 003-005.

Copyright: © 2015 Mostofi K, et al. This is an open access article distributed under the Creative Commons Attribution License, which permits unrestricted use, distribution, and reproduction in any medium, provided the original work is properly cited.

ABSTRACT

Teratomas represent about 0.5% of all intracranial tumours and 2-4% of intracranial tumours in children. They generally arise from brain midline structures such as suprasellar region, pineal gland, quadrigeminal plate, walls of the third ventricle and cerebellar vermis. Teratomas localized in the lateral ventricle are extremely rare. We report a case of massive intracranial teratoma of lateral ventricle related with the choroid plexus in a 2-day-old female. She was born to the first pregnancy of a 26-year-old healthy woman. The pregnancy was uneventful until the 32nd week of gestation. Antenatal ultrasound scan discovered a massive macrocephaly with hydrocephalus and a right lateral ventricular choroid plexus mass. A caesarean section was performed because of failed vaginal delivery. The newborn weighed 2790g and her head circumference was 42 cm. During the first day, she presented oxygen desaturation several times and died on the second day after a cardiac arrest. An autopsy was performed. The histologic diagnosis was immature teratoma made.

KEYWORDS: Immature teratoma, Intracranial congenital tumour, Hydrocephalus, Macrocephaly

INTRODUCTION

Congenital intracranial tumours are very rare and account for 0.5-1.5% of all pediatric brain tumours [1-4]. According to Schlembach D et al. [4] the most common type of these tumours is teratoma. Teratoma is located predominantly in supratentorial brain and in midline structure such as pineal gland, quadrigeminal plate, walls of the third ventricle, suprasellar region and cerebellar vermis. Its location in the lateral ventricle is extremely rare. We report a case of intracranial immature teratoma in a 2-day-old female presenting with macrocephaly and hydrocephalus which diagnosed as a brain tumour by ultrasound investigation and confirmed at autopsy.

CASE REPORT

A 26-year-old healthy primigravida was followed for a normal pregnancy with a normal ultrasonography at 20th week. At 32th week of gestation ultrasound investigation revealed a massive macrocephaly with hydrocephalus due to a right lateral ventricular choroid plexus mass. A week later another Ultrasound scan confirmed the diagnosis and showed tumour growth increase. Because of macrocephaly labour was induced at 34th week with palliative care project for the infant at birth in accordance with family. The fetus was delivered by caesarean section because of failed induction of labour after 48 hours. The newborn weighed 2790g, had a massive macrocephaly and her head circumference was 42 cm. The fontanels were enlarged and there were split cranial sutures. Otherwise, the infant had normal appearing body. After delivery, he breathed after a few seconds and cries openly at ten minutes. During the first day, he presented oxygen desaturation many a time and died on the second day after a cardiac arrest.

An autopsy was performed. Cranial bones were extremely thin. A huge tumour from choroid plexus of the right lateral ventricle was noticed and remnant brain tissue was deformed and hard to identify (Figure 1).

Macroscopically; the tumour was crumbly, whitish and firm in consistency. Histologically, the lesion was composed of multipart and disordered and polymorphic tissues and contained cystic and glandular structures; mesenchymal tissue, cartilaginous and muscle structure. Immunohistochemical examination demonstrated positivity for Desmin, Clarétinine, NSE, Caldesmone and smooth muscle actin and a great positivity for E-cadherine. CD34 showed abundant vascularization of immature type (Figure 2-3). Diagnosis of immature teratoma was therefore made.

DISCUSSION

Congenital brain tumours are rare. Intracranial immature teratoma comprises 0.4% of all pediatric brain tumours [7]. It constitutes the most common of germ cell tumours [9]. Teratoma is formed during the first fourth weeks of embryonic development [12]. The prevalence and female to male ratio of teratoma are unclear and the data of the literature are contradictory [13,15-16]. The most common locations for Teratoma are median structure such as cerebellar vermis, quadrigeminal plate, walls of the third ventricle, pineal gland and suprasellar region. Its occurrence in lateral ventricle is extremely rare. The first intracranial teratoma was reported by Breslau [11] in 1864 and the first teratoma of the lateral ventricle

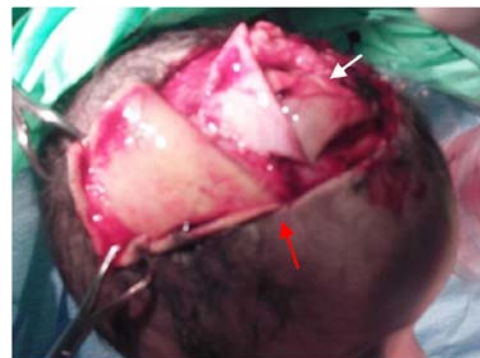

Figure 1: Craniotomy (red arrow) during autopsy shows that the tumour occupies all intracranial space (white arrow) and remnant brain tissue was deformed and hard to identify.

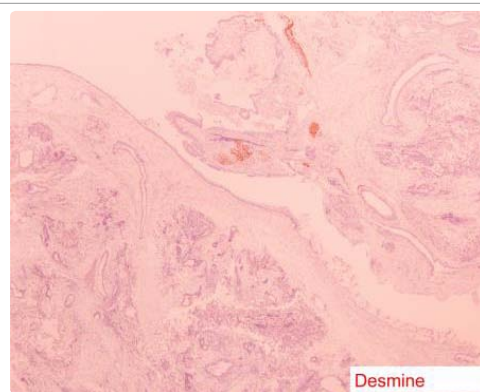


Figure 2: Tumour cells positive for Desmine Image is taken with a 20x objective.

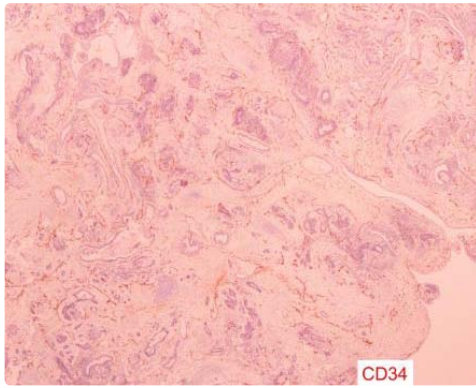


Figure 3: Sparse staining of CD34 Image is taken with a 20x objective.

was reported in 1961 by Maier [5]. Three types of teratoma have been described histologically: mature, immature and malignant. The prenatal detection of congenital intracranial tumours is becoming easier and more common due to ample accessibility of Ultrasound scan. However the distinction between teratoma and other intracranial tumours is not always possible. Intracranial immature teratoma has a massive intrauterine growth. The reasons of this massive growth allowing tumour to replace the normal tissue brain are unclear. Some authors consider that foetal phase offers a better environment for growth of the immature elements [14,15]. Clinically, intracranial teratoma symptomised by macrocephaly, hydrocephalus and infants delivered by caesarean section because of failed induction labour and large head size in infants. The prognosis is extremely poor and infants are stillborn or die very soon after birth. The intrauterine and postnatal management of these tumours are unclear because of their rarity. Recently, some authors proposed Computerized tomography especially MRI for diagnosis of Intracranial teratoma [8,10,12,16,17-20].

REFERENCES

1. Isaacs H, Jr. Perinatal (congenital and neonatal) neoplasms: A report of 110 cases. *Pediatr Pathol* 1985; 3: 165-216.
2. Rickert CH, Probst-Cousin S, Louwen F, Louwen F, Feldt B, Gullotta F. Congenital immature teratoma of the fetal brain. *Child's Nerv Syst.* 1997; 13: 556-559.
3. Balestrini MR, Micheli R, Ciordano L, Lasio G, Giombini S. Brain tumors with symptomatic onset in the first two years of life. *Child's Nerv Syst.* 1994; 10: 104-110.
4. Schlembach D, Bornemann A, Rupprecht T, Beinder E. Fetal intracranial tumors detected by ultrasound: a report of two cases and review of the literature *Ultrasound Obstet Gynecol.* 1999; 14: 407-418.
5. Jain A, Dixit S, Datar S, Jain PK. Large choroid plexus teratoma: a rare cause of congenital hydrocephalus. *Indian J Pediatr.* 2010; 77: 452-453.
6. Yamashita N, Kanai H, Kamiya K, Togari H, Nakamura T. Immature teratoma producing alpha-fetoprotein without components of yolk sac tumor in the pineal region. *Child's Nerv Syst.* 1997; 13: 225-228.
7. Soares FA, Fischer SE, Reis MA Soares EG. Massive intracranial immature teratoma. Report of a case with polyhydramnios and intense pelvic pain. *Arq Neuropsiquiatr.* 1996; 54: 309-312.
8. Arslan E, Usul H, Baykal S, Eyüboğlu EE, Reis A. Massive congenital intracranial immature teratoma of the lateral ventricle with retro-orbital extension: a case report and review of the literature. *Pediatr Neurosurg.* 2007; 43: 338-342.
9. Erman T, Göçer IA, Erdoğan S, Güneş Y, Tuna M, Zorludemir S. Congenital intracranial immature teratoma of the lateral ventricle: a case report and review of the literature. *Neurol Res.* 2005; 27: 53-56.
10. Sinha VD, Dharker SR, Pandey CL. Congenital intracranial teratoma of the lateral ventricle. *Neurol India.* 2001; 49: 170-173.
11. Breslau RE. Geburtgeschichte und untersuchung eines falles von foetus in foetu Virchows. *Arch Path Anat* 1864; 30 : 406-417.
12. Uken P, Sato Y, Smith W. MR findings of malignant intracranial teratoma intracranial a neonate. *Pediatr Radiol.* 1986; 16: 504-505.
13. Arun Thakran, Seema Rao, Sreenivas M, Khurana N. Massive congenital intracranial immature teratoma: An autopsy report *Indian J Pathol Microbiol.* 2012; 55: 272-274.
14. Saiga T, Osasa H, Hatayama H, Miyamoto T, Ono H, Mikami TI. The origin of extragonadal teratoma: case report of an immature teratoma occurring in a prenatal brain. *Pediatr Pathol.* 1991; 115: 759-770.
15. Rostad S, Kleinschmidt-DeMasters BK, Manchester DK. Two massive congenital intracranial immature teratomas with neck extension. *Teratology.* 1985; 32: 163-169.
16. Uken P, Sato Y, Smith W. MR findings of malignant intracranial teratoma in a neonate. *Pediatr Radiol.* 1986; 16: 504-505.
17. Buetow PC, Smimiotopoulos JG, Done S. Congenital brain tumors: a review of 45 cases. *AJR* 1990; 155: 587-593.
18. Ferreira J, Eviatar L, Schneider S, Grossman R. Prenatal diagnosis of intracranial teratoma: prolonged survival after resection of a malignant teratoma diagnosed prenatally by ultrasound. A case report and literature review. *Pediatr Neurosurg* 1993; 19: 84-88.
19. Oi S, Tamaki N, Kondo T, Nakamura H, Kudo H, Suzuki H, et al. Massive congenital intracranial teratoma diagnosed in utero. *Child Nerv Syst.* 1990; 6: 459-461.
20. Richards SR. Ultrasonic diagnosis of intracranial teratoma in utero: a case report and literature review. *J Reprod Med* 1987; 12: 73-75. □