



Scientific Journal of Neurology & Neurosurgery

Research Article

Gamma Knife Surgery Targeting the Neurovascular Contact Complex in Management of Refractory Idiopathic Trigeminal Neuralgia: Outcome and Long Term Efficiency -

Raef F. A. Hafez^{1*}, Tiit Rahn², Magad. S. Morgan³, Osama. M. Fahmy⁴,
Yasser. O. Riyad⁵ and Hamdy. T. Hassan⁶

¹Department of Neurosurgery and gamma knife, Head of Gamma Knife Center -International Medical Center (IMC) Cairo, Egypt

²Department of Neurosurgery, Karolinska University Hospital Stockholm, Sweden

³Consultant Neurosurgery and Gamma knife-International Medical Center (IMC), Cairo, Egypt

⁴Consultant neurosurgery and Gamma Knife - International Medical Center (IMC), Cairo, Egypt

⁵Consultant Neurosurgery at kobbry el koppa hospital, Cairo, Egypt

⁶Registrar Neurosurgery -International Medical Center (IMC), Cairo, Egypt

***Address for Correspondence:** Raef Farouk Ahmed Hafez, Department of Neurosurgery and Gamma Knife Center, International Medical Center (IMC), Cairo, Egypt, Fax: +2024774546; E-mail: raefhafez179@hotmail.com

Submitted: 04 February 2017; **Approved:** 16 February 2017; **Published:** 20 February 2017

Citation this article: Hafez RFA, Rahn T, Morgan MS, Fahmy OM, Riyad YO, et al. Gamma Knife Surgery Targeting the Neurovascular Contact Complex in Management of Refractory Idiopathic Trigeminal Neuralgia: Outcome and Long Term Efficiency. Scientific Journal of Neurology & Neurosurgery. 2017;3(1): 015-021.

Copyright: © 2017 Hafez RFA, et al. This is an open access article distributed under the Creative Commons Attribution License, which permits unrestricted use, distribution, and reproduction in any medium, provided the original work is properly cited.



ABSTRACT

Background: Typical Idiopathic Trigeminal Neuralgia (ITN) is considered to be one of the most severe forms of pain in the human experience. The presence of Neurovascular Contact Complex (NVC) on pre-treatment high resolution Magnetic Resonance Imaging (MRI) predicts an increased likelihood of an adequate response to Gamma Knife Surgery (GKS).

Objective: Evaluation of GKS effectiveness, possible complications, and predicating factors in management of refractory ITN when targeting neurovascular contact complex as the main detected associative pathology with this disease, through retrospective analyze of long term results achieved at our center.

Methods: Fifty eight patients with medically refractory ITN treated by GKS at our institution were followed up between 2005 and 2014. Mean maximum dose was 78 Gy (70-80 Gy). The NVC complex delineated by 3D-T2 MRI sequence of high resolution MRI was the target of GKS radiation. Clinical response was categorized on basis of pain outcome using BNI pain scale. We considered Group I as significant response without medication, Group II as adequate response with medication and Group III as failure to control pain. Mean duration of follow-up was 66 months (24 - 132 months).

Results: significant and Adequate response at last follow-up were achieved in 82.8% of patients , significant response alone without medication was achieved in 60.3% while failure to control pain was in 17.2% of patients. Favorable treatment response rates were significantly higher in patients who had no previous surgery 83%, with duration of symptoms < 10 years 77% and in 75% of those had no sensory dysfunction prior to GKS. New or worsening tolerable facial numbness was reported in 27.5%. New or worsening tolerable facial numbness was reported in 27.5%. At final outcome patients who achieved and maintaining significant and adequate pain control (Group I and Group II) were 82.8% at 2 years, 80% at 3 years, 77% at 5 years and 66% at 10 years.

Conclusion: GKS targeting NVC complex as the main detected associative pathology for treatment of ITN resulted in favorable outcomes compared with surgery in terms of pain relief and complication rates. GKS is a reasonable initial least minimally invasive surgical option for refractory ITN and for those unwilling or medically unsuitable to undergo other surgical approaches.

Keywords: Gamma knife surgery; Idiopathic trigeminal neuralgia; Radio surgery; Rhizotomy

ABBREVIATIONS

BNI: Barrow Neurological Institute; CISS: Constructive Interference Steady State; CSF: Cerebro Spinal Fluid; FIESTA: Fast Imaging Employing Steady-State Acquisition; GKS: Gamma Knife Surgery; ITN: Idiopathic Trigeminal Neuralgia; MRI: Magnetic Resonance Image; MVD: Micro vascular Decompression; NVC: Neurovascular Contact

INTRODUCTION

Blood vessel compression or contact (NVC) complex with the trigeminal nerve is often a common association and probably the cause of idiopathic trigeminal neuralgia [1]. The presence of NVC on pre-treatment MRI predicts an increased likelihood of a favorable response to GKS. Treatment with GKS provides adequate pain control in about 70%-90% of the patients with intractable ITN [2-5].

Pathologic findings of the trigeminal nerve samples from ITN patients have demonstrated axonal loss, axonopathy, demyelination, residual myelin debris. The resulting structural deformity has been blamed for abnormal contacts between different fibers in the nerve, giving rise to the pain paroxysms. It is therefore conceivable that NVC provides a continued source of irritation to a nerve already damaged by other pathological processes such as demyelination or viral infection [4-8].

Medical management remains the mainstay of treatment for trigeminal neuralgia, drugs relieve pain in approximately two third of patients. 25% to 50% of idiopathic trigeminal neuralgia patients are refractory to medical management, even with higher doses or several drugs. In such cases, it may be necessary to resort to surgery including Microvascular Decompression (MVD) or percutaneous rhizotomy, radiofrequency rhizotomy, glycerol rhizolysis, micro balloon compression, and alcohol block. All of these procedures, except for MVD are ablative procedures, which are associated with variable but definite rates of facial numbness and or recurrence. In

spite of high rates of pain control after MVD yet it carries risks related to posterior fossa craniotomy and non-negligible rates of numbness and pain recurrences [3,5,9,10].

Gamma Knife surgery is a minimally invasive surgical approach for managing trigeminal neuralgia. In 1951, Lars Leksell advocated radio surgery using a prototype guiding device linked to a dental x-ray machine [11,12]. During the last 50 years, new versions of gamma knife devices and gamma plan software were developed and in the presence of high resolution MRI, ITN pain control with GKS is steadily improved (77%-90%) [12,3,13,14].

Several factors favorably affect the ability of GKS to relieve pain in ITN patients. These factors include the absence of multiple sclerosis, higher dose of radiation, no previous surgery, the absence of atypical features, presence of NVC with the nerve and the proximity of the isocenter to the brainstem [5,15].

GKS is starting to gain consideration as a first-line of minimally invasive surgical procedure for treatment medical lyre factory ITN [6,16]. Repeat GKS in patients whose pain has recurred after the initial GKS is also accepted with very low or no risks [3,16].

OBJECTIVE

The present retrospective study evaluates the effectiveness of GKS in management of refractory idiopathic trigeminal neuralgia when targeting the neurovascular contact complex as the main association factor with this disease, through retrospective analyzes of long term results achieved at our center. The durability of pain relief, predicating factors for pain control and the possible risks yielded are reported and analyzed.

METHODS AND PATIENT POPULATION

Between 2005 and 2014, 58 patients with typical Idiopathic trigeminal neuralgia treated with Gamma Knife Surgery (GKS) at the International Medical Center (IMC) Cairo - Egypt with a mean follow

of 66 months (24 - 132 months) with a minimum of 2 years follow-up. All patients had long-standing pain refractory to medical and / or prior surgical management. Trigeminal neuralgia patients with bilateral symptoms, atypical facial pain, and demyelinating disease, with tumors or those not completed the follow up was excluded from this study. All patients had long-standing disabling pain refractory to medical management with comprehensive trials of medical therapy that included carbamazepine; many patients also received phenytoin, baclofen, and/or gabapentin, alone or in combination with carbamazepine. 15 patients (26%) had in addition prior surgeries with failure to control pain included Microvascular Decompression (MVD) in 5 patients, glycerol and alcohol rhizotomies in 6 and radiofrequency rhizotomies in 4 patients . Indications for GKS included failure of pharmacologic treatments to provide significant pain relief, failure of prior surgery, or significant adverse effects from medication. Failure of previous therapy was defined as persistent disabling pain lasting a minimum of 6 months since initiation of the prior therapy. GKS was performed with informed consent and different surgical alternatives were explained to the patients. The mean duration of symptoms before GKS in our study were 6.7 years (1-16 years), 43 patients (74%) had a history of trigeminal pain < 10 years.

Most patients remain on full doses of medication for at least 1-3 months after GKS and tapering of medications began when pain relief has been started or achieved.

In our series, 34 patients (58.6%) were men and 24 patients 24 were women (41.4%). The mean age was 52 years (30 - 78 years). Pain was unilateral in all patients, at right side in 32 patients (55%) and at the left side in 26 patients (45%). Distribution of pain was predominantly in the V2-V3 distribution of the trigeminal nerve in 22patients (37.9%), V3distribution in 17 patients (29.3%), in all trigeminal branches in 12patients (20.7%), V2 in 3 patients (5.2%), V1-V2 in 2 patients (3.4%) and V1 in 2 patients. Twenty-one patients (36%) presented with facial sensory dysfunction pre-GKS mainly numbness (Table 1).

GAMMA KNIFE TECHNIQUE AND IMAGING

Gamma knife-Elekta Instruments are used in this study. After application of the Leksell Model G stereotactic frame (Elekta Instruments) under local anesthesia and mild sedation, patients under went stereotactic MRI (1.5 and 3 Tesla) imaging to identify the trigeminal nerve anatomy and the neurovascular contact complex.

The stereotactic MRI protocol for gamma knife treatment of ITN included Axial pre-contrast three-dimensional T2 MRI sequences (3D-T2 MRI) in 0.7 mm slices thickness with long TR values. Axial 3D-T2 MRI is accentuation of the T2 values between cerebrospinal fluid, anatomical and pathological structures demonstrating cranial nerves, CSF, cisternal spaces and cavernous sinus. Axial pre-contrast three-dimensional T2 MRI (3D-T2 MRI) is a modification of FIESTA-MRI protocol (Fast Imaging Employing Steady-state Acquisition) and CISS-MRI protocol (Constructive Interference Steady State) but with long TR values so enhancing the appearance of the blood vessels in contact or compressing the trigeminal nerve which was detected as low signal dark segments against background of bright hyper intense CSF. Axial and Coronal T1-weighted MRI sequences with contrast were also obtained for confirmation of the nerve anatomy and vessels relation, such sequences done in 1 mm slice thickness on zero angles with no gap.

Table 1: The preoperative characteristics in the studied 58 refractory ITN patients treated by GKS.

Patients characteristics		
Variable	Total (58 patients)	
Age/patient-years		
• Mean	52y	
• Range	30-78y	
Sex /patient		
• Male	34	58.6%
• female	24	41.4%
Location/patient		
• Right side	32	55%
• Left side	26	45%
Trigeminal pain distribution /patient		
• V1	2	3.4%
• V2	3	5.3%
• V3	17	29.3%
• V1 & V2	2	3.4%
• V2&v3	22	37.1%
• V1 &V2&V3	12	20.7%
Previous procedures		
• None	43	74%
• Yes	15	26%
Pre-GKS sensory dysfunction		
• Normal	37	64%
• Numbness	21	36%
Duration of symptoms pre-GKS-years		
• Mean	6.7y	
• Range	1-16y	
• <10 Years/ pat*	43	74%
• >10 years/ pat*	15	26%
Follow up period post-GKS/month		
• Mean	66mos	
• Average	24-132 mos	
GKS procedures		
• Fist procedure	52	
• Repeated procedure	6	

The presence of vascular contact with the trigeminal nerve was determined and diagnosed when contact of the blood vessel and the nerve was clearly detected in two or more sections of the axial 3D T2 images. The identification of the responsible blood vessel for NVC complex was performed with complete observation of all the images including post-contrast Axial and Coronal T1 MRI images. For the image analysis, the transverse original images, the coronal and sagittal reformatted images, and the other reformatted images obtained parallel and perpendicular to the trigeminal nerve (Figure 1).

Gamma Plan software version 10.1 (Elekta) is used for dose plan and drawing of both the trigeminal nerve form the pons till the ganglion and the NVC complex which is used as the target of treatment . It was possible to identify NVC complex in all studied patients by using the 3D-T2 MRI sequence with prolonged TR values even with atrophic trigeminal nerve or with regional perineural fibrosis due prior surgical attempts.

A single 4 mm isocenter was used in all patients targeting the detected neurovascular contact complex of the trigeminal nerve. The mean maximum given dose to the target was 78 Gy (70-80 Gy), 2-3 mm brain stem adjacent to the NVC complex target received 10-22 Gy (Figure 2).

Facial and vestibule coclear nerves do not received > 8 Gy, semicircular apparatus received < 8 Gy, cochlea < 8 Gy and temporal lobe received < 12 Gy.

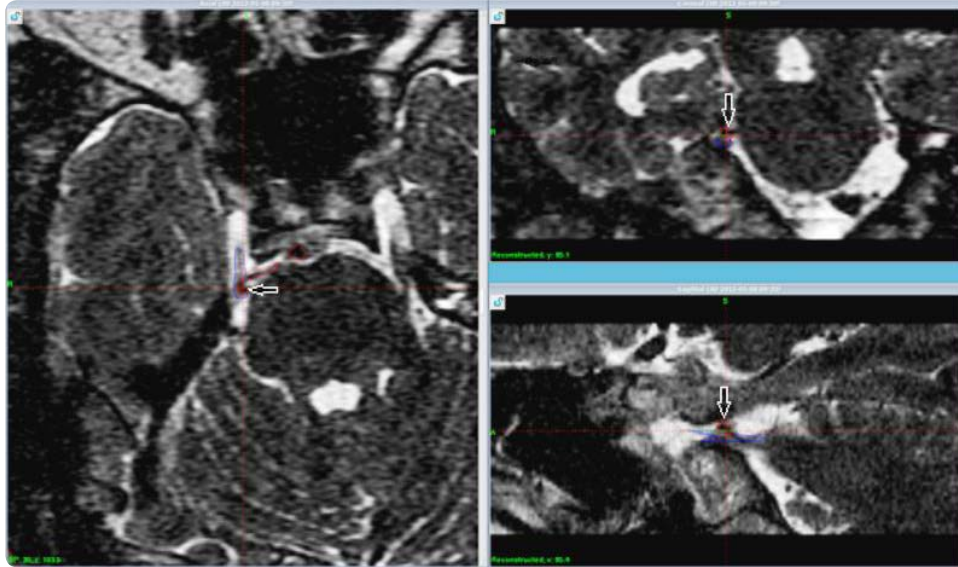


Figure 1: Axial 3D-T2 MRI with long TR value without contrast for 58 years old male patient with right side idiopathic trigeminal neuralgia treated with GKS to detected NVC complex displaying in gamma knife plan workstation showing the right trigeminal nerve as blue lined drawn structure and the detected blood vessel in contact (NVC complex) which is pointed to by white arrows in reconstruction Coronal and Sagittal images.

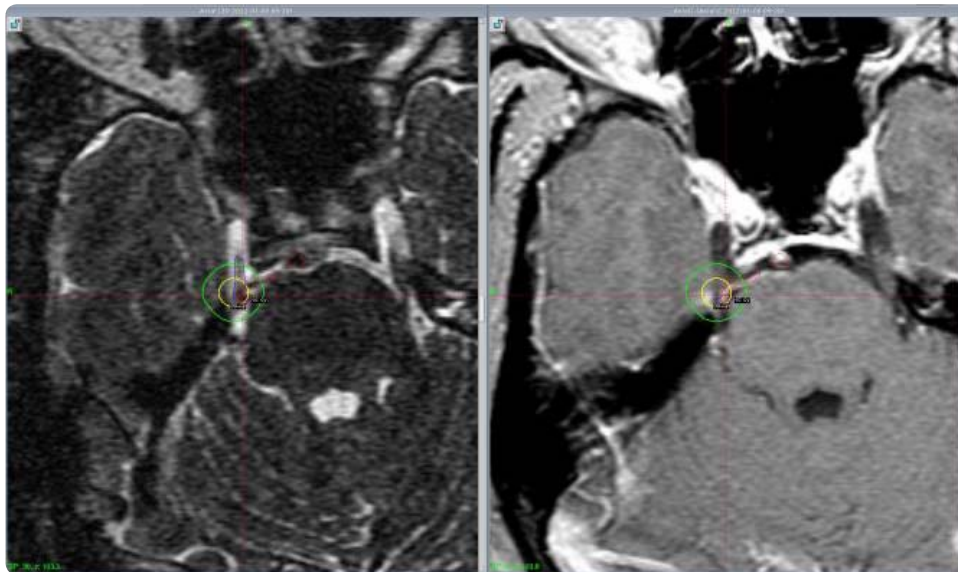


Figure 2: Axial 3D-T2 pre-contrast MRI and post contrast Axial T1 MRI images of the same patient in Figure 1 at gamma dose plan workstation showing the right trigeminal nerve which is drawn as blue lined structure and the blood vessel in contact which is drawn as red lined structure in both images confirm simultaneously the existence of NVC complex which is used as the target for GKS in treatment.

FOLLOW UP

Follow up done for clinical evaluation after 3, 6 and 12 months in the first year post-GKS then yearly afterward and MRI with contrast obtained after 12 months then if needed. The mean follow-up duration was 66 months with a minimum of 2 years follow-up.

All serial follow-up information were obtained via direct contact at the outpatient clinic or via telephone contact by physician involved in gamma knife treatment. We evaluated the degree of pain relief, period till pain relief, the use of medications, further surgical procedures, and the development or worsen of symptoms or signs.

Pain outcome was scored using the Barrow Neurological Institute (BNI) scale [4,17]. Patients pain outcome were categorized into

three groups; Group I patients with significant pain relief without medication of (BNI grade I-II), Group II with adequate pain relief with medication of (BNI grade IIIa-IIIb) and Group III represented treatment failures even with multiple or high dose of medication of (BNI grade IV-V). Patients who described new or worsen preexisting facial sensory dysfunction were reported.

RESULTS

At the end of our retrospective study the proportion of patients in Group I was 60.3% (35 patients) with significant pain relief outcome, in Group II was 22.4% (13 patients) with adequate pain relief with medication, and in Group III was 17.2% (10 patients) that represent GKS failure to control the trigeminal pain.

INITIAL RESPONSE AND MAINTENANCE OF PAIN RELIEF

In the majority of studied patients the latency period for pain relief was started or achieved at 1-3 months and considered as failure after one year. Two patients reported pain relief in less than a month post- GKS.

In the 48 patients (82.8%) who represented Group I and Group II together who achieved adequate and significant pain relief the mean maximum given doses were 78 Gy (70-80Gy). Among these two groups 40 patients (83%) did not have prior surgery, 37 patients (77%) had a history of trigeminal pain < 10 years and 36 patients (75%) did not have facial sensory dysfunction pre-GKS. Nine patients (18.8%) did developed new or worsen existed facial numbness post-GKS.

Failure of gamma knife to provide adequate pain relief in our study is reported in 10 patients (17.2%) who represented Group III, the average maximum given dose to those patients was 70Gy, Seven (70%) patients in Group III had previous surgical procedures, 9 patients (90%) presented with sensory facial numbness pre-GKS and 7 patients (70%) had worsen existed facial numbness post-GKS.

Six patients required additional gamma knife treatment with mean radiation dose of 70 Gy and two patients did additional thermal radiofrequency rhizotomy, all of such procedures done at 1 to 2 years after the initial GKS.

At final outcome patients who achieved and maintaining significant and adequate pain control at last follow up (Group I and II) were 82.8% at 2 years, 80% at 3 years, 77% at 5 years and 66% at 10 years (Table 2).

Table 2: Final pain relief outcomes in the studied 58 ITN patients treated with GKS targeting NVC Complex using the Barrow Neurological Institute (BNI) scale.

Patients Groups	Number of patients	%
Group I (BNI I-II) Patients Achieved significant pain relief without medication	35 patients	60.4%
Group II (BNI IIIa-IIIb) Patients Achieved adequate pain relief with medication	13 patients	22.4%
Group III (BNI IV-V) Patients with Failure of GKS to control pain	10 patients	17.2%

POST GAMMA KNIFE COMPLICATIONS

No patient in this study sustained an early complication after GKS. Later developed complications were limited to facial sensory dysfunction mainly numbness. New or worsened facial numbness was reported in 16 patients (27.5%), 10 of them did have worsened existed facial numbness and 6 developed new facial numbness. Numbness was non bothersome in 13 patients and somewhat bothersome in three patients who were on medication. Neither corneal ulceration or anesthesia dolorosa nor clinical or radiological ischemic micro vascular events were noted during the follow-up period.

DISCUSSION

The role of GKS in the management of medically refractory idiopathic trigeminal neuralgia has evolved. Questions regarding treatment durability, long-term complications, and appropriate patient selection have challenged physicians to place GKS in the

context of other therapeutic modalities for this disorder [2].

By the end of the 20th century, Micro Vascular Decompression (MVD) emerged as the gold standard for medically refractory trigeminal neuralgia with rates of long-term excellent results between 68 and 90%. The mortality rate reported is approximately 0.3%, and severe neurological complications occur in 1.7% [6,17-21].

Unfortunately many patients with trigeminal neuralgia are poor craniotomy candidates due to advanced age or the presence of medical co morbidities or unwilling to do surgery. Stereotactic GKS is the least minimally invasive modality for such patients in addition to those failed to obtain pain relief after other surgical procedures [15,21].

To achieve controlling trigeminal pain, there should be a balance between surgical risks, maintenance of normal nerve function, and the known rates for pain relief. Not all procedures relieve pain and not all patients can or want to stop medication. Many Authors consider GKS as the preferred minimally invasive option if medication fails for ITN [2,5].

In our article, we detail a relatively long-term outcome in uniform patient's population with ITN targeting NVC. We reported a higher positive response rates (adequate and significant pain control) in 93% of the 43 patients who did not undergone previous surgical procedures prior to GKS compare to 53% in 15 patients who had previous surgical procedures, although these results are slightly higher but close similar to other published series [3,22,23].

Brisman, et al. [18] reported better GKS responses in patients with vascular contact to the trigeminal nerve revealed by high resolution MRI, who had not had previous surgery with 96% response in classes I, II.

Erbay, et al. [19] in their series indicated that 83% patients with NVC on MRI scans had a good initial response to GKS compared with 40% in those without detectable NVC.

In our series it was possible to delineated NVC complex in all studied 58 patients by using stereotactic pre-contrast axial 3D-T2 images with prolongation of TR values with high resolution MRI. In 98% of studied patients NVC was small vessels and in one patient it was a larger vessel. 82.8% of patients in our series achieved significant and adequate pain control at last follow up. These results are close to others, nevertheless GKS isocenter in our series was targeting a detectable NVC complex as it is the main associative pathology with this disease regardless its proximity to the root entry zone.

Pollock, et al. [21] in describing a series of 117 patients treated with gamma knife radio surgery for idiopathic trigeminal neuralgia targeting the root entry zone of the trigeminal nerve with a maximal dose between 70 and 90 Gy, reported 55% of the patients were pain-free and without medication after 3 years. The authors reported new persistent trigeminal sensory dysfunction in 37% of the patients.

Sheehan, et al. [15] communicated the results for 151 patients with trigeminal neuralgia treated with gamma knife radio surgery to the root entry zone of trigeminal nerve using a maximal dose between 50 and 90 Gy. After a median follow-up period of 19 months, 70% experienced some degree of pain relief at 3 years. Nine percent of the patients experienced new facial numbness after treatment.

Regis, et al. [23] reported that 83 of 100 trigeminal neuralgia patients treated with gamma knife surgery to the retro gasseriancisternal portion of the fifth cranial nerve with minimum

of 12 month follow up were reported to be pain free at last visit. The median dose used at the maximum was 85 Gy (range 70-90 Gy). Fifty-eight of these 83 patients had stopped taking medication during the study. Six patients reported facial paresthesia, and four patients reported hypesthesia.

In our article among the 48 patients (82.8%) who achieved the favorable outcome (Group I-II), 37 patients (77%) had history of trigeminal pain < 10 years, 40 patients (83%) did not have prior surgery and 36 patients did not have facial sensory dysfunction pre-GKS. The mean maximum given dose to those patients was 78 Gy (70-80 Gy).

Failure of gamma knife to provide adequate pain relief in our study was reported in 10 patients (17.2%) represented Group III, the mean maximum given dose was 70 Gy, 7 of them (70%) had previous surgical procedures and 7 patients showed worsen existed facial numbness post - GKS.

Complications in our study were limited to facial sensory dysfunction in form of numbness. New or worsened facial numbness was reported in 16 patients (27.5%).

At final outcome in our series for 58 ITN patients treated with GKS targeting the NVC, patients who achieved and maintaining significant and adequate pain relief without or with medication at last follow up were 82.8% at 2 years, 80% at 3 years, 77% at 5 years and 66% at 10 years follow - up period.

The overall results of the present study in terms of pain outcome and complications do not differ significantly from those of other published although the target of radiation was different but still alongside of the trigeminal nerve [3,5,9,20,23,24]. However, the main objective of the present article in addition to evaluate GKS efficiency and safety was to try to correlate pain outcomes when GKS when targeting the NVC complex as the main associative detected pathology in management of refractory ITN.

Favorable results in this study were obtained in ITN patients targeting the NVC complex who did not have pre - gamma knife surgical procedures, with duration of symptoms < 10 years, who have no facial sensory dysfunction pre - GKS and who received mean maximum radiation dose of 78Gy. These findings could be considered as predicating prognostic factors in the management of ITN with GKS.

STRENGTHEN AND LIMITATIONS

This retrospective study presents a symmetrical uniform group of typical refractory Idiopathic trigeminal neuralgia patients; all treated by the same medical team at a single center. Mean follow-up was 66 months (24 - 132 months).

Still larger number of patients and longer term of effectiveness are warranted for standardized prognostic factors and determine the role GKS as a proposed first line of minimally invasive procedures for treatment refractory ITN patients.

CONCLUSION

GKS is a minimally invasive procedure resulting in significant and adequate pain relief in our study in 82.8% of treated patients with ITN when targeting NVC complex as the main associative detected pathology, with the mean follow up of 66 months. Morbidity is tolerable and lower than with other minimally invasive surgical alternatives. A duration of symptoms < 10 years pre-GKS, mean

maximum radiation dose of 78 Gy, and no prior surgery indicate favorable responses. GKS is a reasonable initial least minimally invasive surgical option for refractory ITN and those unwilling or medically unsuitable to undergo other surgical approaches.

CONFLICT OF INTEREST

All authors certify that they have no affiliation with or involvement in any organization or entity with any financial interest (such as honoraria; educational grants; participation in speakers' bureaus; membership, employment, consultancies, stock ownership, or other equity interest; and expert testimony or patent-licensing arrangements), or non-financial interest (such as personal or professional relationships, affiliations, knowledge or beliefs) in the subject matter or materials discussed in this manuscript.

AUTHOR'S CONTRIBUTIONS

Raef Farouk Ahmed Hafez: Conceived, Design, prepared and reviewed the manuscript. TiiT Rahn reviewed the manuscript. Magad S. Morgan participated in the design of the study. Osama M. Fahm participated in preparing and design of the study. Yasser Omar Riyad and Hamdy Thabet Hassan participated in preparing the study. The manuscript final version was approved by all authors.

ETHICAL APPROVAL

The current article is a retrospective studies "For this type of study formal consent is not required.

REFERENCES

1. Kang JH, Yoon YS, Kang DW, Chung SS, Chang JW. Gamma knife radio surgery for medically refractory idiopathic trigeminal neuralgia. *Acta Neurochir Suppl.* 2008; 101: 35-8.
2. Kondziolka D, Zorro O, Lobato-Polo J, Kano H, Flannery TJ, Flickinger JC, et al. Gamma Knife stereotactic radiosurgery for idiopathic trigeminal neuralgia. *J Neurosurg.* 2010; 112: 758-65.
3. Martínez Moreno NE, Gutiérrez-Sárraga J, Rey-Portolés G, Jiménez-Huete A, Martínez Álvarez R. Long-Term Outcomes in the Treatment of Classical Trigeminal Neuralgia by Gamma Knife Radio surgery: A Retrospective Study in Patients with Minimum 2-Year Follow-up. *Neurosurgery.* 2016; 79: 879-888.
4. Erbay SH, Bhadelia RA, Riesenburger R, Gupta P, O'Callaghan M, Yun E, et al. Association between neurovascular contact on MRI and response to gamma knife radiosurgery in trigeminal neuralgia. *Neuroradiology.* 2006; 48: 26-30.
5. Sindou M, Howeydy T, Acevedo G. Anatomical observations during micro vascular decompression for idiopathic trigeminal neuralgia (with correlations between topography of pain and site of the neurovascular conflict). Prospective study in a series of 579 patients. *Acta Neurochir (Wien).* 2002; 144: 1-12.
6. Dhople AA, Adams JR, Maggio WW, Naqvi SA, Regine WF, Kwok Y. Long-term outcomes of Gamma Knife radio surgery for classic trigeminal neuralgia: implications of treatment and critical review of the literature. *J Neurosurg.* 2009; 111: 351-8.
7. Devor M, Govrin-Lippmann R, Rappaport ZH. Mechanism of trigeminal neuralgia; an ultrastructural analysis of trigeminal root specimens obtained during microvascular decompression surgery. *J Neurosurg.* 2002; 96: 532-43.
8. Tenser RB. Trigeminal neuralgia: mechanisms of treatment. *Neurology.* 1998; 51: 17-9.
9. Kondziolka D, Perez B, Flickinger JC, Habek M, Lunsford LD. Gamma knife radio surgery for trigeminal neuralgia: results and expectations. *Arch Neurol.* 1998; 55: 1524-9.
10. Somaza S, Hurtado W, Montilla E, Ghaleb J. Gamma knife radio surgery to the trigeminal ganglion for treatment of trigeminal neuralgia secondary to



vertebrobasilar ectasia. *Surg Neurol Int.* 2014; 5: S580-5.

11. LEKSELL L. The stereotaxic method and radio surgery of the brain. *Acta Chir Scand.* 1951; 102: 316-9.
12. Leksell L. Stereotaxic radio surgery in trigeminal neuralgia. *Acta Chir Scand.* 1971; 137: 311-4.
13. McNatt SA, Yu C, Giannotta SL, Zee CS, Apuzzo ML, Petrovich Z. Gamma knife radiosurgery for trigeminal neuralgia. *Neurosurgery.* 2005; 56: 1295-301.
14. Pollock BE. Comparison of posterior fossa exploration and stereotactic radio surgery in patients with previously nonsurgically treated idiopathic trigeminal neuralgia. *Neurosurg Focus.* 2005; 18: E6.
15. Sheehan J, Pan HC, Stroila M, Steiner L. Gamma knife surgery for trigeminal neuralgia: outcomes and prognostic factors. *J Neurosurg.* 2005; 102: 434-41.
16. Boecher-Schwarz HG, Bruehl K, Kessel G, Guenther M, Perneczky A, Stoeter P. Sensitivity and specificity of MRA in the diagnosis of neurovascular compression in patients with trigeminal neuralgia. A correlation of MRA and surgical findings. *Neuroradiology.* 1998; 40: 88-95.
17. Levy EI, Jannetta PJ. Microvascular decompression, in Burchiel KJ (ed): *Surgical Management of Pain.* New York: Thieme; 2002. p. 878-886.
18. Brisman R. Microvascular decompression vs gamma knife radiosurgery for typical trigeminal neuralgia: Preliminary findings. *Stereotact Funct Neurosurg.* 2007; 85: 94-8.
19. Erbay SH, Bhadelia RA, Riesenburger R, Gupta P, O'Callaghan M, Yun E, et al. Association between neurovascular contact on MRI and response to gamma knife radiosurgery in trigeminal neuralgia. *Neuroradiology.* 2006; 48: 26-30.
20. Lorenzoni JG, Massager N, David P, Devriendt D, Desmedt F, Brotchi J, et al. Neurovascular compression anatomy and pain outcome with classic trigeminal neuralgia treated by radiosurgery. *Neurosurgery.* 2008; 62: 368-75.
21. Pollock BE, Phuong LK, Gorman DA, Foote RL, Stafford SL. Stereotactic radiosurgery for idiopathic trigeminal neuralgia. *J Neurosurg.* 2002; 97: 347-53.
22. Maesawa S, Salame C, Flickinger JC, Pirris S, Kondziolka D, Lunsford LD. Clinical outcomes after stereotactic radiosurgery for idiopathic trigeminal neuralgia. *J Neurosurg.* 2001; 94: 14-20.
23. Régis J, Metellus P, Hayashi M, Roussel P, Donnet A, Bille-Turc F. Prospective controlled trial of gamma knife surgery for essential trigeminal neuralgia. *J Neurosurg.* 2006; 104: 913-24.
24. Barker FG 2nd, Jannetta PJ, Bissonette DJ, Larkins MV, Jho HD. The long-term outcome of microvascular decompression for trigeminal neuralgia. *N Engl J Med.* 1996; 334: 1077-83.