



International Journal of Orthopedics: Research & Therapy

Case Report

Recurrent Bilateral anterior Simultaneous Dislocation of The Shoulder Following Epileptic Seizures : A Rare Lesional Association - @

Ibrahima Farikou^{1*}, Guifo Marc Leroy¹, Handy Eone Daniel¹, Nana Chunteng Theophil¹ and Sosso Maurice Aurelien¹

¹Faculty of Medicine and Biomedical Sciences, University of Yaounde I, Cameroon

***Address for Correspondence:** Ibrahima Farikou, Faculty of Medicine and Biomedical Sciences, University of Yaounde I, Cameroon, P.O. Box 14572 Yaounde, Tel: (+237)99870267; E-mail : ifarikou@hotmail.com

Submitted: 09 August 2017; **Approved:** 23 August 2017; **Published:** 25 August 2017

Citation this article: Ibrahima F, Guifo ML, Handy Eone D, Nana Chunteng T, Sosso, MA. Recurrent Bilateral anterior Simultaneous Dislocation of The Shoulder Following Epileptic Seizures : A Rare Lesional Association. A Review. Int J Ortho Res Ther. 2017;1(1): 006-009.

Copyright: © 2017 Ibrahima F, et al. This is an open access article distributed under the Creative Commons Attribution License, which permits unrestricted use, distribution, and reproduction in any medium, provided the original work is properly cited.

ABSTRACT

Bilateral dislocations of the shoulder are rare. Posterior bilateral dislocations are often associated with convulsive seizures of various origins, whereas bilateral anterior dislocations are usually the result of a violent mechanism. We report a rare case of recurrent simultaneous anterior bilateral dislocation associated with epileptic seizures in a 31-year-old man. To the best of our knowledge, no similar cases have been reported in the literature.

INTRODUCTION

Shoulder dislocation occurs quite frequently and are seen in the daily practice of the orthopedic surgeon. Bilateral dislocation of the shoulder, which is infrequent, is often associated with epileptic crises [1-3] or electrocution and are the most common cause of posterior bilateral dislocations, whereas bilateral anterior dislocations are most often associated with trauma [4-12], especially in young subjects. Bilateral anterior dislocations secondary to convulsions are very rare [13]. Bilateral anterior dislocations are even more rare. Only a few cases have been reported in the literature [8].

We report a rare case of a recurrent simultaneous anterior dislocation of the shoulder secondary to convulsive seizures, occurring in a young man of 31 years old in two episodes at an interval of 2 years. This is the only case observed in our service in 18 years of practice. Moreover, no similar case has been reported to the best of our knowledge.

The two shoulders were reduced under general anesthesia and immobilized by a temporary arthrodesis with 2 crossed pins completed by an elbow-to-body Dessault bandage for 6 weeks. This double internal and external restraint was followed by early rehabilitation.

The short- and medium-term outcome was satisfactory.

CLINICAL REPORT

We present a young man of 31 years old, right-handed, who was recently received in a remote peripheral hospital of about 600 km from our town and who was evacuated by train to our service. He was received 6 days after the injury in our emergency department.

In his medical history, we noticed that another episode of dislocation occurred 2 years ago in the same circumstances, that is to say, following a convulsion crisis of undetermined origin. The initial bilateral simultaneous dislocation seen on that same day in emergency room of a peripheral hospital was reduced and immobilized for 3 weeks. On physical examination at the emergency, we noticed a total loss of function of both upper limbs fixed in abduction that was irreducible. In addition, we noticed the "épaulette sign" and a prominence of the acromion [Figure 1]. In the lateral view, an antero-internal enlargement of the 2 shoulders. On palpation there was a vacuity of the subacromial space, a painful mobility with attempted rotation of the upper limbs. The peripheral pulse, in particular axillary, humeral, radial and ulnar, were perfectly perceived on both sides. The motor and sensory neurological examination of the radial, cubital and median nerve areas were normal.

Standard plain X-Rays assessment of the 2 shoulders confirmed the diagnosis of bilateral anterior-internal dislocation [Figure 2]. Computed Tomography (CT) profined the diagnosis and, in addition, showed the existence of a bilateral Malgaigne (or Hill Sachs) notch of the glenoid on the posterior margin of the humeral head and gliding of the anterior inferior border of the glenoid [Figure 3].

The biological check-up showed no significant abnormality, particularly a normal fasting blood sugar of 0.90g / l. The Electroencephalographic tracing (EEG) was normal. We programmed emergency surgery to be carried out under general anesthesia including a reduction and internal fixation (temporary arthrodesis by 2 cross pins) and external restraint by the elbow-to-body Dessault bandage. This reduction was done, under general anesthesia with maximum muscular relaxation, and progressive soft maneuvers described by Kocher : traction in the axis of each upper limb, external rotation and abduction [Figure 4].

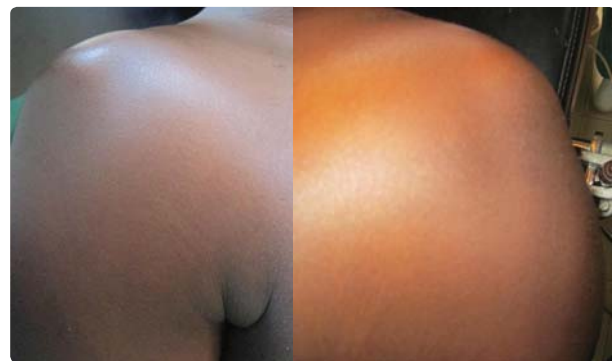

Figure 1: A.Y: appearance of the 2 dislocated shoulders just before reduction maneuvers under general anesthesia.

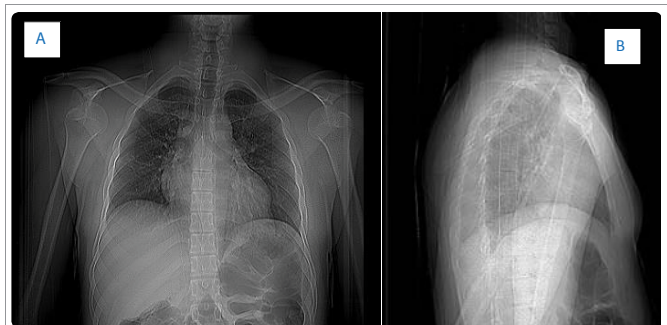


Figure 2: A. Y. 31 years old, face (A) and profile (B) standard x-rays: simultaneous recent anterior internal bilateral dislocation.

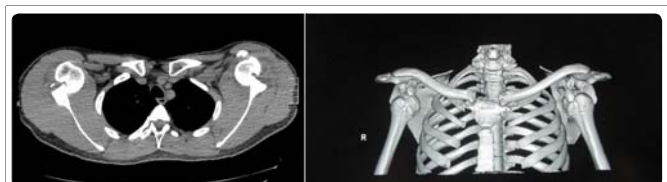

Figure 3: Same patient: computed tomography with reconstruction images: bilateral dislocation with bilateral notch of Malgaigne (or fracture of Hill Sachs).

The postoperative control radiographs showed a perfect reduction [Figure 5].

Despite the normal post-critical EEG tracing, the patient was placed on Phenobarbital (Gardéнал™) by the neurologist-epileptologist of the department on the basis of an anamnestic and a clinical examination. Early rehabilitation was undertaken as soon as the double contention was removed to favor the progressive recovery of the passive, active-passive and active articular amplitudes of the 2 shoulders. Stability tests after removal of the immobilization at day 45 and before the patient's exit after 20 sessions of rehabilitation were satisfactory. The Single Assessment Numeric Evaluation (SANE score : 0 to 100), was done for self-evaluation of shoulder function. It was estimated at Day 75 and Day 345, at 30 and 80 respectively.

DISCUSSION

Epidemiologically, because of its anatomy and biomechanics (the most mobile enarthrose in the body), the shoulder is the joint that is most susceptible to dislocations accounting for 50% of all dislocations. The majority of these dislocations are anterior, the posterior dislocations representing only 3% to 5% of the dislocations of the shoulder. About 1% of shoulder dislocations result in fractures.

Concerning the etiological mechanism, bilateral anterior dislocations are very often attributed to trauma [4-12], especially with high energy trauma in young subjects. A review of 90 bilateral shoulder dislocations conducted by Brown [14], revealed that 49% were due to epileptic convulsions or electrocution, 23% were traumatic and 36% were non-traumatic. For our case it was a bilateral dislocation, rare, simultaneous and recurrent, that could be related to a convulsive crisis even if the hypoglycemic or epileptic origin is not formally established. EEG and fasting blood glucose were normal. Some authors have attributed the occurrence of posterior dislocation of the shoulder to convulsions caused by induced hypoglycemia [15], or severe vitamin D deficiency [16].

From a therapeutic point of view, the relative early nature of the dislocation, the relatively small stature of the Hills-Sachs notch and the young age of our patient led us to opt for orthopedic treatment. The fear of another recurrence and the young age of the patient prompted us to do both an internal and external restraint and an immobilization for 6 weeks, long enough to ensure stability of both shoulders though with risk of residual stiffness easily corrected by an early rehabilitation. The medical treatment of convulsive seizures also contributed to the prevention of another recurrence.

A wide range of therapeutic methods of bilateral shoulder dislocation according to the etiology and clinical presentation are proposed in the literature with various outcomes. The most usual conservative treatment is reduction by external manoeuver Milch [17], Kocher [8,13] or more recently Spaso technique [18] under general or local anesthesia by infiltration and immobilization followed by suitable early rehabilitation [17-20]. Conservative treatment is indicated most often for uncomplicated anterior bilateral dislocations, seen relatively early. Surgical treatment is reserved for the majority of authors to bilateral posterior dislocations associated with fractures particularly Hill-Sachs lesions. Surgical methods comprise open reduction and internal fixation [1,9], hemiarthroplasty or total shoulder arthroplasty with or without osteochondral auto or allografts in case of significant bone defects [3,9,21]. Tendon (subscapularis) transfers sometimes could be done by 2 surgical teams [22].

CONCLUSION

Bilateral dislocation of the shoulder is often associated with a violent traumatic mechanism. This clinical case and the literature taught us that recurrent simultaneous anterior bilateral dislocation may also have a comitial origin. An orthopedic reduction followed by a sufficiently long immobilization in young subjects and the use of an anticonvulsive medical treatment are alternatives to open reduction, and effective in preventing recurrences.

RÉFÉRENCES

- Sheth H, Salunke AA, Panchal R, Choksi J, Nambi GI, Singh S, et, al. Simultaneous bilateral shoulder and acetabular fracture-dislocation : What to do ? Chin J traumatol, 2016; 19: 59-62. <https://goo.gl/FNfNCV>
- Sahbudin I, Filer A. Nocturnal seizure and simultaneous bilateral shoulder fracture-dislocation. BMJ Case Rep 2016; 2: 2016. <https://goo.gl/k9mPKT>
- Elmali N, Taşdemir Z, Sağlam F, Gulabi D, Baysal O. One stage surgical treatment of neglected simultaneous bilateral locked posterior dislocation of shoulder : a case report and literature review. Eklem Hastalik Cerrahisi 2015; 26: 175-80. <https://goo.gl/NftWR6>
- Barlow M, Lynch R. Sequential bilateral anterior dislocation of shoulder. Am J Emerg Med 2016; 34: 939. <https://goo.gl/fCo1nu>
- Auerbach B, Bittermann A, Mathew C, Healy W 3rd. Bilateral Shoulder Dislocation Presenting as a Unilateral Shoulder Dislocation : Case Report. J Am Osteopath Assoc. 2015; 115: 514-7. <https://goo.gl/nRhrJP>
- Choulapalle R, Chokkarapu R, Kolluri RK, Anne SR, Perumal SR, Avadhanam PK, Bheemanathuni R. A case of neglected bilateral anterior shoulder dislocation : a rare entity with unusual mechanism of injury. Case Rep Orthop. 2015; 2015: 461910. <https://goo.gl/K66Fkn>
- Noureddine H, El Sayad M, Gull S, Davies AP. Bilateral anterior shoulder dislocation. BMJ Case Rep. 2013; 29: 2013. <https://goo.gl/PqZ3hr>
- Patil MN. A Case Report of Simultaneous bilateral anterior shoulder dislocation. J Orthop Case Rep. 2013; 3: 35-7. <https://goo.gl/vsVDuC>
- Jansen H, Frey SP, Dohst S, Meffert RH. Simultaneous posterior fracture dislocation of the shoulder following epileptic convulsion. J Surg Case Rep. 2012; 4: 2012. <https://goo.gl/d1z52b>

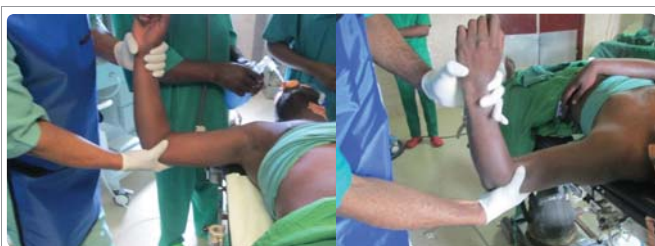

Figure 4: Same patient: External reduction maneuvers: axis traction, external rotation and abduction.

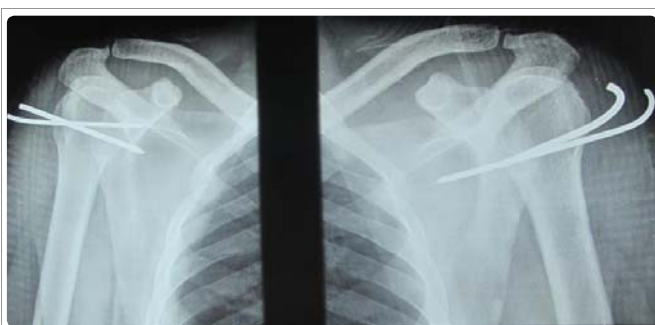

Figure 5: A.Y. 31 years old: the anteroposterior radiographs of the 2 shoulders confirm the anatomical reduction.

10. Kalkan T, Demirkale I, Ocguder A, Unlu S, Bozkurt M. Bilateral anterior shoulder dislocation in two cases due to housework accidents. *Acta Orthop Traumatol Turc.* 2009; 43: 260-3. <https://goo.gl/twMPbL>
11. Felderman H, Shih R, Maroun V. Chin-up-induced bilateral anterior shoulder dislocation: a case report. *J Emerg Med.* 2009; 37: 400-2. <https://goo.gl/4K41da>
12. Lin CY, Chen SJ, Yu CT, Chang IL. Simultaneous bilateral anterior fracture dislocation of the shoulder with neurovascular injury: report of a case. *Int Surg.* 2007; 92: 89-92. <https://goo.gl/LdgY4F>
13. Suryavanshi A, Mittal A, Dongre S, Kashyap N. Bilateral Anterior Shoulder Dislocation with Symmetrical Greater Tuberosity Fracture following Seizure. *J Orthop Case Rep.* 2012; 2: 28-31. <https://goo.gl/bjv3AT>
14. Brown RJ. Bilateral dislocation of the shoulders. *Injury.* 1974; 15: 267-73. <https://goo.gl/9iJNb8>
15. Langenhan R, Hohendorff B, Trobisch P, Probst A. Simultaneous bilateral humeral head dislocation and acetabular fracture. A rare manifestation after hypoglycemia-induced seizures. *Unfallchirurg.* 2014; 117: 747-51. <https://goo.gl/Ae3shn>
16. O'Neil D, Nair JR, Binymin KA. Simultaneous bilateral posterior dislocation of the shoulder in a young man with unexpected severe vitamin D deficiency. *Int J Gen Med* 2012; 5: 399-402. <https://goo.gl/wnnHCW>
17. Kumar YC, Nalini KB, Maini L, Nagaraj P. Bilateral traumatic anterior dislocation of shoulder; A rare entity. *J Orthop Case Rep.* 2013; 3: 23-5. <https://goo.gl/o6Phuj>
18. Singh S, Kumar S. Bilateral anterior shoulder dislocation: a case report. *Eur J Emerg Med.* 2005; 12: 33-5. <https://goo.gl/3HQfwN>
19. Randimbirinina ZL, Ralahy MF, Rohimpitiavana HA, Rabemazava AZLA, Razafimahandry HJC. Bilateral anterior dislocation of lepaule: clinical case and review of literature. *Rev Trop Chir* 2016; 10: 4-5.
20. Tripathy SK, Sen RK, Aggarwal S, Dhatt SS, Tahasildar N. Simultaneous bilateral anterior shoulder dislocation : report of two cases and review of literature. *Chin J Traumatol.* 2011; 14: 312-5. <https://goo.gl/44nWkr>
21. Uppal HS, Robinson PW, Packham I, Crowther M. The management of bilateral posterior fracture dislocation of the shoulder : a case series illustrating management options. *Shoulder Elbow.* 2016; 8: 111-7. <https://goo.gl/MbXSW4>
22. Allende C, Bustos D, Bruno P, Galera H. Two-team simultaneous open surgical treatment in bilateral shoulder fracture dislocation. 2012; 16: 210-4. <https://goo.gl/W99t6L>