



# Open Journal of Surgery

## Review Article

# Gossypiboma (Retained Surgical Sponge): an Evidence-Based Review -

**Abdul Rehman<sup>1</sup>, Noor Ul-Ain Baloch<sup>1</sup>, Muhammad Awais<sup>2\*</sup>**

<sup>1</sup>Teaching Associate, Department of Biological & Biomedical Sciences, Aga Khan University, P.O. box 3500, Stadium Road, Karachi 74800, Sindh, Pakistan.

<sup>2</sup>Assistant Professor, Department of Radiology, Dow University of Health Sciences, Ojha Campus, Suparco Road, Karachi, Sindh, Pakistan.

**\*Address for Correspondence:** Muhammad Awais, Assistant Professor, Department of Radiology, Dow University of Health Sciences, Ojha Campus, Suparco Road, Karachi 75300, Sindh, Pakistan. Tel: (+92)-300-9034827; E-mail: awais\_aku@yahoo.com

**Submitted:** 02 September 2017; **Approved:** 06 September 2017; **Published:** 07 September 2017

**Cite this article:** Rehman A, Ul-Ain Baloch N, Awais M. Gossypiboma (Retained Surgical Sponge): an Evidence-Based Review. Open J Surg. 2017;1(1): 008-014.

**Copyright:** © 2017 Awais M, et al. This is an open access article distributed under the Creative Commons Attribution License, which permits unrestricted use, distribution, and reproduction in any medium, provided the original work is properly cited.



## ABSTRACT

Gossypiboma is an infrequent but devastating consequence of a human error. Most often, patients present with vague clinical features and the diagnosis is made several years after the initial surgical procedure. Diagnosis of a gossypiboma has important clinical and medico legal implications and therefore, patients must be provided accurate information in an appropriate manner to help them make informed decisions. Prevention of such untoward incidents can be achieved by improving communication amongst members of the operating team and strictly adhering to sponge-counting protocols. Awareness among all general physicians, surgeons and radiologists regarding this important clinical entity is vital to vouchsafe patient safety and prevent unnecessary morbidity.

**Keywords:** Gossypiboma; Retained Surgical Sponges; Medical Errors.

## INTRODUCTION

Gossypiboma refers to a foreign body—a retained surgical sponge—and it is a direct consequence of human error [1]. This term has its roots in gossipium (“cotton” in Latin) and boma (“place of concealment” in Kiswahili) [2]. The first published report of a gossypiboma dates back to 1884 [3]. Since then, many standardized protocols of sponge counting [4] and use of radio plaque sponges [5] have been implemented; however, such mishaps continue to happen even today [6]. Despite the morbidity associated with gossypiboma, this disorder remains an obscure entity within the medical community and most physicians seldom consider it in their differential diagnoses [7, 8]. Here, we provide an evidence-based review of this infrequent—yet clinically significant—entity.

### Epidemiology

The exact incidence of this disorder is difficult to determine as it is seldom reported due to its associated medico legal implications [9]. However, estimates based on various retrospective studies suggest that a foreign body is retained in 1 of every 1000 to 1500 abdominal surgeries [10]. For the purpose of this article, a search of Pub Med, Ovid and EMBASE databases was performed using the keywords “gossypiboma” OR “retained surgical sponges” and all publications retrieved were reviewed. Furthermore, all articles referenced in these articles were also manually reviewed. Using this method, we could find 340 cases reported in 254 peer-reviewed publications, which pertained to nearly all surgical specialties including general surgery, cardiothoracic surgery, obstetrics and gynecology, orthopaedics, urology and neurosurgery (Figure 1).

### Pathogenesis

Once retained in the body, surgical gauze act as foreign bodies and induce a strong inflammatory response. An infiltrate comprising of polymorph nuclear leukocytes is seen initially followed by a mononuclear infiltrate, which eventually results in the formation of a foreign-body type granuloma [11]. Chronic inflammation leads to proliferation of fibroblasts, production of granulation tissue and deposition of collagen fibres. Over time, a conglomerate mass is formed and dystrophic calcification can occur within it [12]. In certain cases, invasion by a mixture of anaerobic and aerobic bacteria can lead to the formation of a frank abscess [13]. Occasionally, inflammation within the lesion may ‘spill over’ to an adjacent organ and this can result in the formation of a fistula. Rarely, this may even lead to spontaneous expulsion of a retained sponge [14-18].

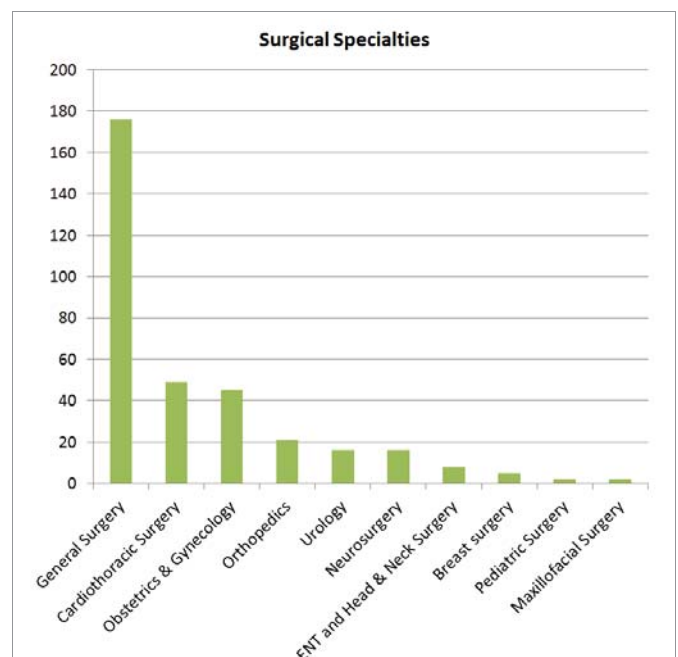
### Clinical features

Patients with gossypiboma often have vague clinical presentations (Table 1) and the diagnosis usually comes as a surprise [79]. Exact clinical symptomatology depends on the site of the retained surgical

sponge. Abdomen, pelvis and thorax have been reported to be the most frequent sites [80]. Patients often present with pain, discomfort, palpable mass or unexplained fever [81]. Irritation of bowel loops, bladder or rectum can lead to vomiting, diarrhoea, hematuria, dysuria, tenesmus and other systemic complaints [82]. Sponges retained within the thoracic cavity can lead to pain and cough [83], while those retained within the cranial cavity can lead to headache, loss of vision or focal neurologic deficits [84]. However, there have been reports of asymptomatic gossypiboma as well [19,21]. As a consequence, the average time interval between the surgical procedure and diagnosis of gossypiboma is approximately 7 years [85].

### Risk factors

Retention of surgical sponges and other foreign objects are widely considered as avoidable mistakes [86]. Consequently, such cases often receive extensive media coverage and result in adverse consequences for the health professionals involved [87,88]. The infrequent occurrence of such errors coupled with their under-reporting precludes the identification of predisposing factors [10]. Nevertheless, a systematic review of 254 cases concluded that ‘emergency surgery’ and ‘poor communication’ are the strongest predictors of a retained surgical sponge [85]. Moreover, in nearly all cases, the sponge count is erroneously believed to be correct at the end of the procedure [89].

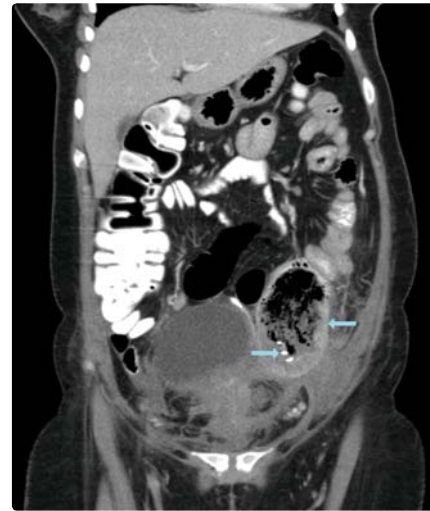

**Figure 1:** Number of reports of gossypiboma published in international peer-reviewed journals with respect to different surgical specialties.

A single-centre retrospective study of 14 cases also identified ‘obesity’ as a risk factor for retained surgical gauze [90].

**Complications**

Gossypiboma retained within the abdomen can have numerous adverse sequela. Acute peritonitis can develop as a result of acute inflammation around the retained foreign body [91,92]. Chronic inflammation can lead to the formation of adhesions, which can precipitate intestinal obstruction [29,30]. Inflammation of surrounding viscera can result in the formation of fistulae and migration of the sponge into the lumen [14,15,54,94]. This in turn can lead to intestinal obstruction [95,96] or, in some cases, spontaneous expulsion of the retained sponge [14-18]. Visceral perforation can also occur with resultant secondary peritonitis [36,97]. In rare cases, the retained gauze may transmigrate into the stomach to result



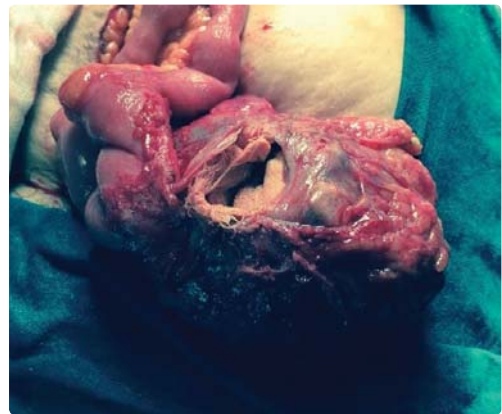**Figure 2:** Computed tomography of the abdomen and pelvis demonstrating a mottled lesion in the left lower abdomen with a coiled metallic density (arrows).

Copyright © 2014 Rehman, Baloch, Awais, licensee Bloomsbury Qatar Foundation Journals. Adapted from: Rehman A, Baloch NU, Awais M. (2014) Gossypiboma diagnosed fifteen years after a cesarean section: A case report. *Qatar Med J.* 2014: 12. This is an open access article distributed under the terms of the Creative Commons Attribution license CC BY 4.0, which permits unrestricted use, distribution and reproduction in any medium, provided the original work is properly cited.

**Table 1:** Various clinical presentations of gossypiboma

Clinical Presentation	Ref. No.	Clinical Presentation	Ref. No.
Asymptomatic	[18]	Fever of unknown origin	[19]
'Incidentaloma'	[20]	Anemia of chronic disease	[21]
Gastrointestinal			
Biloma*	[22]	Gastric lesion	[23]
Gall-bladder lesion	[24]	Appendiceal tumor*	[25]
Hepatic lesion	[26]	Intestinal tumor*	[11]
Pancreatic lesion	[27]	Intestinal obstruction	[28]
Splenic lesion	[29]	Intestinal polyp*	[30]
Intra-abdominal abscess	[31]	Mesenteric cyst*	[32]
Blumer's shelf†	[33]	Upper GI hemorrhage	[34]
Defecated spontaneously	[15]	Intestinal perforation	[35]
Respiratory			
Tracheal foreign body	[36]	Bronchiectasis*	[37]
Pulmonary nodule	[38]	Tuberculosis*	[39]
Pleural lesion	[40]	Recurrence of lung cancer*	[41]
Diaphragmatic abscess	[42]	Mediastinal mass	[43]
Cardiovascular			
Cardiac mass	[44]	Pericardial lesion	[45]
Recurrent syncope	[46]		
Genitourinary			
Perinephric abscess	[47]	Renal neoplasm*	[48]
Bladder outflow obstruction	[49]	Bladder neoplasm*	[50]
Acute urinary retention	[51]	Bladder stone*	[52]
Ureteroappendiceal fistula	[53]	Per vaginal bleeding	[54]
Testicular lesion	[55]	Spontaneous per-urethral extrusion	[56]
Ovarian lesion	[57]		
Neurological			
Spinal mass	[58]	Paraspinal abscess	[59]
Paraspinal tumor*	[60]	Lumbar abscess	[61]
Psoas abscess	[62]	Chronic lumbago	[63]
Intracranial tumor*	[64]		
Musculoskeletal			
Lesion of hip	[65]	Lesion of knee	[66]
Tumor of femur*	[67]	Non-healing sinus on leg	[68]
Recurrent thigh lesion	[69]	Shoulder abscess	[70]
Soft tissue sarcoma*	[71]	Pathologic fracture of femur	[72]
Lesion of mandible	[73]		
Other			
Neck mass	[74]	Salivary fistula	[75]
Abdominal wall lesion	[76]	Nasoethmoidal lesion	[77]

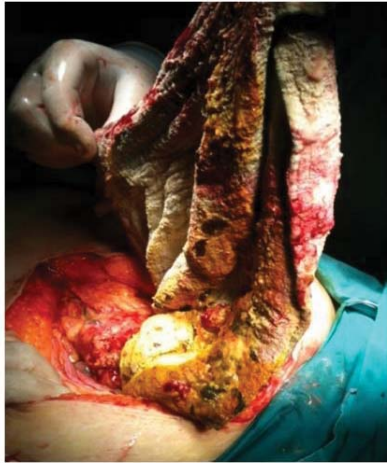\* Gossypiboma misdiagnosed as this disorder.  
 † A lesion in the pouch of Douglas, which is palpable on digital rectal examination as a 'shelf.'  
 GI = Gastrointestinal; Ref. No. = Reference number as given in the list of references.



**Figure 3:** Intraoperative picture of a lump adherent to bowel loops with a gossypiboma visible inside.

Copyright © 2014 K. N. Srivastava and Amit Agarwal. Reproduced from: Srivastava KN, Agarwal A. (2014) Gossypiboma posing as a diagnostic dilemma: a case report and review of the literature. *Case Rep Surg.* 2014: 713428. This is an open access article distributed under the Creative Commons Attribution License, which permits unrestricted use, distribution, and reproduction in any medium, provided the original work is properly cited.

in upper gastrointestinal bleeding [35], or erode the bladder wall to precipitate bladder outflow obstruction [98]. Few incidents of Ureteric obstruction with proximal hydro nephrosis have also been reported in the literature [99].



**Figure 4:** Intraoperative picture of a retained sponge removed after exploratory laparotomy.

Copyright © 2013 TahsinColak et al.

Reproduced from: Colak T, Olmez T, Turkmenoglu O, Dag A. (2013) Small Bowel Perforation due to Gossypiboma Caused Acute Abdomen. *Case Rep Surg.* **2013**: 219354. This is an open access article distributed under the Creative Commons Attribution License, which permits unrestricted use, distribution, and reproduction in any medium, provided the original work is properly cited.

## Diagnosis

Diagnosis of gossypiboma is often difficult to make and requires a high index of suspicion [100]. In patients presenting with a long-standing history of vague symptoms, the possibility of a gossypiboma must be kept in mind [101,102]. During history taking, it is important to establish the chronology of symptoms and whether they relate to a particular surgical procedure [81]. Equally important is to inquire about the patient's past surgical history and specifically regarding the nature of surgeries (i.e. Elective or Emergency). A focused physical examination must be performed to exclude other pathologies. Imaging modalities, especially CT and magnetic resonance imaging, can accurately delineate the lesion and identify its characteristic features [38,103-106]. Most often, gossypiboma appear as spongiform lesions with mottled lucencies and gas bubbles [107,108]. On a CT scan, a characteristic pattern of calcification can be noted along the architectural network of a surgical sponge—the “calcified reticulate rind” sign [109]. Moreover, gossypiboma present within the bowel result in the formation of prominent longitudinal folds, which are visible on a wide range of window settings on a CT scan; this is termed the “stretched faces” sign [110].

## Management

Once a gossypiboma is suspected based on clinical presentation and radiologic findings, the first and foremost step is to inform the patient clearly regarding what has happened and how it can be rectified. Cooperation between the primary physician, radiologist and a surgeon can help streamline patient care and allow the patient take an informed decision. The treatment in all such cases is surgical removal of the retained foreign object [111]. Pathologic evaluation of the resected specimen is warranted to confirm the diagnosis and exclude other pathologies [112].

## Prevention

Gossypiboma is a direct consequence of human error and extensive research has been conducted on the prevention of this iatrogenic disorder. Sponge-counting protocols [4] and use of radiopaque sponges [5] have been implemented across the globe in this regard. However, cases of gossypiboma still occur [6] and this has led to the development of several other strategies. Sponges with radiofrequency identification tags have been devised, which can be detected automatically by a machine, thereby removing the ‘human’ element in the process [113-115]. Bar-coding of surgical sponges has also been tried, which also shows promise for reducing the incidence of such errors [116]. Some preliminary decision-analytic models have even demonstrated the feasibility and cost-effectiveness of these measures [117]. However, these technologies are still in their incipient stages and their implementation across the globe will only be possible if they are able to stand the test of time. As of now, sponge counting is often mentioned as the “gold standard” for prevention of gossypiboma.

## CONCLUSION

Gossypiboma is an infrequent but devastating consequence of a human error. Prevention of such untoward incidents is far better than cure and can be achieved by strictly adhering to sponge-counting protocols and improving communication amongst nurses, technicians and surgeons. At the same time, awareness among all general physicians, surgeons and radiologists regarding this important clinical entity is vital to vouchsafe patient safety and prevent unnecessary morbidity.

## REFERENCES

- Williams RG, Bragg DG, Nelson JA. Gossypiboma—the problem of the retained surgical sponge. *Radiology.* 1978; 129: 323-6. <https://goo.gl/9EoL6C>
- Werbin N. [Gossypiboma?]. *Harefuah.* 2006; 145: 606-629. <https://goo.gl/uJh2zd>
- Wilson CP. Foreign bodies left in the abdomen after laparotomy. *GynecolTr.* 1884;9: 109–112.
- Lutgendorf MA, Schindler LL, Hill JB, Magann EF, O'Boyle JD. Implementation of a protocol to reduce occurrence of retained sponges after vaginal delivery. *Mil Mil Med.* 2011; 176: 702-4. <https://goo.gl/HK6vr4>
- Revesz G, Siddiqi TS, Buchheit WA, Bonitatibus M. Detection of retained surgical sponges. *Radiology.* 1983; 149: 411-3. <https://goo.gl/1wtEZC>
- Bani-Hani KE, Gharaibeh KA, Yaghan RJ. Retained surgical sponges (gossypiboma). *Asian J Surg.* 2005; 28: 109-15. <https://goo.gl/Lmmwhz>
- Sakorafas GH, Sampanis D, Lappas C, Papantoni E, Christodoulou S, Mastoraki A, et al. Retained surgical sponges: what the practicing clinician should know. *Langenbecks Arch Surg.* 2010; 395: 1001-7. <https://goo.gl/uKjHnq>
- Rehman A, Baloch NU, Awais M. Gossypiboma: an unrecognized and under-reported problem in Pakistan. *J Coll Physicians Surg Pak.* 2014; 24: 956. <https://goo.gl/uwFmjH>
- Biswas RS, Ganguly S, Saha ML, Saha S, Mukherjee S, Ayaz A. Gossypiboma and surgeon- current medicolegal aspect - a review. *Indian J Surg.* 2012; 74: 318-322. <https://goo.gl/Zwhm7N>
- Gawande AA, Studdert DM, Orav EJ, Brennan TA, Zinner MJ. Risk factors for retained instruments and sponges after surgery. *N Engl J Med.* 2003; 348: 229-235. <https://goo.gl/v4awCs>
- Hyslop JW, Maull KI. Natural history of the retained surgical sponge. *South Med J.* 1982; 75: 657-660. <https://goo.gl/cWFC5a>
- Şahin-Akyar G, Yağci C, Aytaç S. Pseudotumour due to surgical sponge: gossypiboma. *Australas Radiol.* 1997; 41: 288-291. <https://goo.gl/K5WNSq>



13. Paramythiotis D, Michalopoulos A, Papadopoulos VN, Panagiotou D, Papaefthymiou L, Digkas E, et al. Gossypiboma presenting as mesosigmoid abscess: an experimental study. *Techniques in Coloproctology*. 2011; 67-69. <https://goo.gl/tyJduZ>
14. Zantvoord Y, van der Weiden RM, van Hooff MH. Transmural migration of retained surgical sponges: a systematic review. *Obstet Gynecol Surv*. 2008; 63: 465-471. <https://goo.gl/sxbYa6>
15. Godara R, Marwah S, Karwasra RK, Goel R, Sen J, Singh R. Spontaneous transmural migration of surgical sponges. *Asian J Surg*. 2006; 29: 44-45. <https://goo.gl/NtSBv6>
16. Choi JW, Lee CH, Kim KA, Park CM, Kim JY. Transmural migration of surgical sponge evacuated by defecation: mimicking an intraperitoneal gossypiboma. *Korean J Radiol*. 2006; 7: 212-214. <https://goo.gl/32s2jw>
17. La Roque GP. A gauze sponge spontaneously expelled from the urinary bladder. *Trans South Surg Assoc*. 1919; 31: 60.
18. Özkan OV, Baş G, Akçakaya A, Şahin M. Transmural migration of a retained sponge through the rectum: a Case Report. *Balkan Med J*. 2011; 28: 94-95. <https://goo.gl/oHoUkl>
19. Cevik I, Dillioglugil O, Ozveri H, Akdas A. Asymptomatic retained surgical gauze towel diagnosed 32 years after nephrectomy. *Int Urol Nephrol*. 2008; 40: 885-888. <https://goo.gl/kbRR1w>
20. Lourenco SC, Baptista A, Pacheco H, Malhado J. A misplaced surgical towel—a rare cause of fever of unknown origin. *Eur J Intern Med*. 2008; 19: 377-378. <https://goo.gl/oETLYJ>
21. Vento JA, Karak PK, Henken EM. Gossypiboma as an incidentaloma. *Clin Nucl Med*. 2006; 31: 176-177. <https://goo.gl/zANvzf>
22. Campos FFD, Franco F, Maximiano LF, Martinês JAS, Felipe-Silva AS, Kunitake TA, et al. An iron deficiency anemia of unknown cause: a case report involving gossypiboma. *Clinics (Sao Paulo)*. 2010; 65: 555-558. <https://goo.gl/U9To71>
23. Sugano S, Suzuki T, Iinuma M, Mizugami H, Kagesawa M, Ozawa K, et al. Gossypiboma: diagnosis with ultrasonography. *J Clin Ultrasound*. 1993; 21: 289-292. <https://goo.gl/GnR4Hh>
24. Disu S, Wijesiriwardana A, Mukhtar H, Eben F. An ileal migration of a retained surgical swab (gossypiboma): a rare cause of an epigastric mass. *J Obstet Gynaecol*. 2007; 27: 212-213. <https://goo.gl/H7fUci>
25. Rajalingam R, Saluja SS, Sharma A, Mishra PK. Post cholecystectomy gossypiboma: a malignant masquerade. *Am Surg*. 2011; 77: E94-5. <https://goo.gl/GjA41b>
26. Sümer A, Carparlar MA, Uslukaya Ö, Bayrak V, Kotan C, Kemik O, et al. Gossypiboma: retained surgical sponge after a gynecologic procedure. *Case Rep Med* 2010; 917626. <https://goo.gl/g1sbvj>
27. Cerwenka H1, Bacher H, Kornprat P, Mischinger HJ. Gossypiboma of the liver: CT, MRI and intraoperative ultrasonography findings. *Dig Surg*. 2005; 22: 311-312. <https://goo.gl/N5h5Ze>
28. Yakan S, Oztürk S, Harman M, Tekesin O, Coker A. Gossypiboma mimicking a distal pancreatic mass: Report of a case. *Cent Eur J Med*. 2010; 5: 136-139. <https://goo.gl/mL9vC2>
29. Sharma D, Pratap A, Tandon A, Shukla RC, Shukla VK. Unconsidered cause of bowel obstruction—gossypiboma. *Can J Surg*. 2008; 5: E34–E35. <https://goo.gl/4cLwzo>
30. Akbulut S, Arikanoglu Z, Yagmur Y, Basbug M. Gossypibomas Mimicking a Splenic Hydatid Cyst and Ileal Tumor. *J Gastrointest Surg*. 2011; 15: 2101-7. <https://goo.gl/PY3yCV>
31. Agarwal AK, Bhattacharya N, Mukherjee R, Bora AA. Intra luminal gossypiboma. *Pak J Med Sci*. 2008; 24: 461-463. <https://goo.gl/rDLcKk>
32. Prasad S, Krishnan A, Limdi J, Patankar T. Imaging features of gossypiboma: report of two cases. *J Postgrad Med*. 1999; 45: 18-19. <https://goo.gl/beqnVS>
33. Moyle H, Hines OJ, McFadden DW. Gossypiboma of the abdomen. *Arch Surg*. 1996; 131: 566-568. <https://goo.gl/32FhFB>
34. Possover M. Images in clinical medicine. Gossypiboma in the pouch of Douglas. *N Engl J Med*. 2008; 359: e9. <https://goo.gl/moTe5a>
35. Erdil A, Kilciler G, Ates Y, Tuzun A, Gulsen M, Karaeren N, et al. Transgastric migration of retained intraabdominal surgical sponge: gossypiboma in the bulbous. *Intern Med*. 2008; 47: 613-615. <https://goo.gl/mWMB3y>
36. Malhotra MK. Migratory surgical gossypiboma—cause of iatrogenic perforation: case report with review of literature. *Niger J Surg*. 2012; 18: 27-29. <https://goo.gl/Wq5wVQ>
37. Falletti J, Somma A, Baldassarre F, Accurso A, D'Etorre A, Insabato L. Unexpected autoptic finding in a sudden death: gossypiboma. *Forensic Sci Int*. 2010; 199: e23-26. <https://goo.gl/m5LqDA>
38. Suwatanapongched T, Boonkasem S, Sathianpitayakul E, Leelachaikul P. Intrathoracic gossypiboma: radiographic and CT findings. *Br J Radiol*. 2005; 78: 851-853. <https://goo.gl/UFWqz2>
39. Park HJ, Im SA, Chun HJ, Park SH, O JH, Lee KY. Changes in CT appearance of intrathoracic gossypiboma over 10 years. *Br J Radiol*. 2008; 81: e61-63. <https://goo.gl/6uqHcc>
40. Rijken M, van Overbeeke AJ, Staaks G. Gossypiboma in a man with persistent cough. *Thorax*. 2005; 60: 708. <https://goo.gl/gKEp5>
41. Okur HK, Okur E, Baran R. Three cases of intrathoracic gossypiboma with varying morbidities depending on the time of detection. *Thorac Cardiovasc Surg*. 2009; 57: 432-434. <https://goo.gl/veFPJG>
42. de Llanos CG, Navarro PC, Gilart JF, Suárez PR, Serhald MH, Saavedra TR. Intrathoracic gossypiboma interpreted as bronchogenic carcinoma. Another false positive with positron emission tomography. *Arch Arch Bronconeumol*. 2007; 43: 292-294. <https://goo.gl/YcJXHc>
43. Solaini L, Prusciano F, Bagioni P. Intrathoracic gossypiboma: a movable body within a pseudocystic mass. *Eur J Cardiothorac Surg*. 2003; 24: 300. <https://goo.gl/iwD4MA>
44. Jian QY, Milestone BN, Parsons RB, Doss M, Haas N. Findings of intramediastinal gossypiboma with F-18 FDG PET in a melanoma patient. *Clin Nucl Med*. 2008; 33: 344-345. <https://goo.gl/WE6APw>
45. Szarf G, de Andrade TCM, Nakano E, Szejnfeld D, Costa AS, Rymkiewicz E et al. Forty-year-old intrathoracic gossypiboma after cardiac valve surgery. *Circulation*. 2009; 119: 3142–3143. <https://goo.gl/JBoEwd>
46. Lerner CA, Dang HP. MR imaging of a pericardial gossypiboma. *AJR Am J Roentgenol*. 1997; 169: 314. <https://goo.gl/1e12V4>
47. Galle K, Desmet W, Herijgers P. Transient loss of consciousness caused by textiloma or gossypiboma. *Eur Heart J*. 2010; 31: 1716-1717. <https://goo.gl/aut7AQ>
48. Bhat HS, Mahesh G, Ramgopal KS. 'Gossypiboma': an unusual cause of perinephric abscess. *J R CollSurgEdinb*. 1997; 42: 277-278. <https://goo.gl/M8t1dA>
49. Hennessey D, Thomas A, Lynch T, Casey R. Retained Upper Genitourinary Gossypiboma Can Mimic Renal Neoplasms. A Review Of The Literature. *Internet J Urol* 2012; 9: 2. <https://goo.gl/2QUnc8>
50. Rafique M. Vesical gossypiboma. *J Coll Physicians Surg Pak*. 2003; 13: 293-295. <https://goo.gl/ntJzDt>
51. Ijaz M. Urinary Bladder Gossypiboma (Retained post operative foreign body in urinary bladder). *Rawal Med J*. 2005; 30: 96-97. <https://goo.gl/JnAo8S>
52. Sun HS, Chen SL, Kuo CC, Wang SC, Kao YL. Gossypiboma—retained surgical sponge. *J Chin Med Assoc*. 2007; 70: 511-513. <https://goo.gl/xeyyWY>
53. Mungadi IA, Attahiru NA, Saidu SA. Vesical Gossypiboma Mimicking Calculus: A Report of two Cases. *African J Urol*. 2007; 13: 136–138. <https://goo.gl/A4RHRw>
54. Yaycioglu O, Ulsan S, Ezer A, Guvel S. Ureteroappendiceal fistula due to gossypiboma. *Urol Int*. 2007; 79: 187-188. <https://goo.gl/8Dnsfg>
55. Wan YL, Ko SF, Ng KK, Cheung YC, Lui KW, Wong HF. Role of CT-guided core needle biopsy in the diagnosis of a gossypiboma: case report. *Abdom imaging*. 2004; 29: 713–715. <https://goo.gl/yZ9mqL>
56. Moslemi MK, Abedinzadeh M. Retained intraabdominal gossypiboma, five years after bilateral orchiopexy. *Case Rep Med*. 2010; 420357. <https://goo.gl/UscrKD>
57. Lin TY, Chuang CK, Wong YC, Liao HC. Gossypiboma: migration of retained surgical gauze and spontaneous transurethral protrusion. *BJU Int*. 1999; 84: 879-880. <https://goo.gl/6WWj2G>

58. Kim CK, Park BK, Ha H. Gossypiboma in abdomen and pelvis: MRI findings in four patients. *American Journal of Roentgenology*. 2007; 189: 814-817. <https://goo.gl/UNtUnP>
59. Okten AI, Adam M, Gezercan Y. Textiloma: a case of foreign body mimicking a spinal mass. *Eur Spine J*. 2006; 15: 626-629. <https://goo.gl/yAaGGy>
60. Is M, Karatas A, Akgul M, Yildirim U, Gezen F. A retained surgical sponge (gossypiboma) mimicking a paraspinous abscess. *Br J Neurosurg*. 2007; 21: 307-308. <https://goo.gl/uM28Xr>
61. Erdem G, Ateş O, Koçak A, Alkan A. Lumbar gossypiboma. *Diagn Interv Radiol*. 2010; 16: 10-12. <https://goo.gl/5kozYD>
62. Karabekir HS, Yildizhan A, Atar EK. Neurosurgical gossypiboma radiologically mimicking a lumbar abscess. *Neurosciences (Riyadh)*. 2007; 12: 163-165. <https://goo.gl/jqTiRR>
63. Kim HS, Chung TS, Suh SH, Kim SY. MR imaging findings of paravertebral gossypiboma. *AJNR Am J Neuroradiol*. 2007; 28: 709-713. <https://goo.gl/XCph1H>
64. Rajković Z, Altarac S, Papeš D. An unusual cause of chronic lumbar back pain: retained surgical gauze discovered after 40 years. *Pain Med*. 2010; 11: 1777-1779. <https://goo.gl/knbu68>
65. Ribalta T, McCutcheon IE, Neto AG, Gupta D, Kumar AJ, Biddle DA, et al. Textiloma (gossypiboma) mimicking recurrent intracranial tumor. *Arch Pathol Lab Med*. 2004; 128: 749-758. <https://goo.gl/Ju8oyf>
66. Iwase T, Ozawa T, Koyama A, Satake K, Tauchi R, Ohno Y. Gossypiboma (foreign body granuloma) mimicking a soft tissue tumor with hip hemiarthroplasty. *J Orthop Sci*. 2007; 12: 497-501. <https://goo.gl/miZsT3>
67. Salzano A, De Rosa A, Borruso G, Giordano G, Gatta G. [A case of gossypiboma of the knee. Its computed tomographic diagnosis]. *Radiol Med*. 2000; 99: 188-189. <https://goo.gl/5hCwTT>
68. Sakayama K, Fujibuchi T, Sugawara Y, Kidani T, Miyawaki J, Yamamoto H. A 40-year-old gossypiboma (foreign body granuloma) mimicking a malignant femoral surface tumor. *Skeletal Radiol*. 2005; 34: 221-224. <https://goo.gl/haR45c>
69. Leijnen M, Steenvoorde P, van Doorn LP, da Costa SA, Schuttevaer HM, van Leeuwen GA, et al. A non-healing sinus of the lower leg 5 years after vacuum-assisted closure therapy due to a gossypiboma. *Wounds*. 2007; 19: 227-230. <https://goo.gl/hy7kjb>
70. Puri A, Anchan C, Jambhekar NA, Agarwal MG, Badwe RA. Recurrent gossypiboma in the thigh. *Skeletal Radiol*. 2007; 36 Suppl 1: S95-100. <https://goo.gl/2RGKiu>
71. Bevernage C, Geusens E, Nijs S. Case report: a gossypiboma in the shoulder. *Emerg Radiol*. 2006; 12: 231-233. <https://goo.gl/XMBjdC>
72. Roumen RMH, Weerdenburg HPG. MR features of a 24-year-old gossypiboma. *Acta Radiol*. 1998; 39: 176-178. <https://goo.gl/EZRpNC>
73. Suh DH, Yoon JR, Kang KB, Han SB, Kim HJ, Lee SJ. A gossypiboma-induced pathological fracture of the proximal femur. *Clin Radiol*. 2009; 64: 1132-1135. <https://goo.gl/FkAd5u>
74. Song SY, Hong JW, Yoo WM, Tark KC. Gossypiboma after mandibular contouring surgery. *J Craniofac Surg*. 2009; 20: 1607-1610. <https://goo.gl/fsJWGF>
75. Niederkoher RD, Hwang BJ, Quon A. FDG PET/CT detection of a gossypiboma in the neck. *Clinical Nuclear Medicine*. 2007; 32: 893-895. <https://goo.gl/xRsVzm>
76. Amr AE. A submandibular gossypiboma mimicking a salivary fistula: a case report. *Cases J*. 2009; 2: 6413. <https://goo.gl/Ma9R7r>
77. Huston TL, Grant RT. Abdominal wall gossypiboma. *J Plast Reconstr Aesthet Surg*. 2010; 63: 463-464. <https://goo.gl/74zWdu>
78. Tan VES, Sethi DS. Gossypiboma: An unusual intracranial complication of endoscopic sinus surgery. *Laryngoscope*. 2011; 121: 879-881. <https://goo.gl/gMP2GQ>
79. Ukwenya AY, Dogo PM, Ahmed A, Nmadu PT. The retained surgical sponge following laparotomy; forgotten at surgery, often forgotten at diagnosis. Our experience. *Niger J Surg Res*. 2006; 8: 164-168. <https://goo.gl/NyZE8n>
80. McIntyre LK, Jurkovich GJ, Gunn ML, Maier RV. Gossypiboma: tales of lost sponges and lessons learned. *Arch Surg*. 2010; 145: 770-775. <https://goo.gl/NyWi3C>
81. Coleman J, Wolfgang CL. Necessity of a good surgical history: detection of a gossypiboma. *J Nurs Pract*. 2013; 9: 277-282. <https://goo.gl/LytTZ4>
82. Rappaport W, Haynes K. The retained surgical sponge following intra-abdominal surgery: a continuing problem. *Arch Surg*. 1990; 125: 405-407. <https://goo.gl/A1omcf>
83. Topal U, Gebitekin C, Tuncel E. Intrathoracic gossypiboma. *AJR Am J Roentgenol*. 2001; 177: 1485-1486. <https://goo.gl/FA8BTH>
84. Moiyadi AV, Pai P, Chaturvedi P, D'Cruz A. Intracranial gossypiboma: An under-reported entity. *Neurol India*. 2010; 58: 492-493. <https://goo.gl/gXTEKV>
85. Wan W, Le T, Riskin L, Macario A. Improving safety in the operating room: a systematic literature review of retained surgical sponges. *Curr Opin Anaesthesiol*. 2009; 22: 207-214. <https://goo.gl/sS4Fq6>
86. Parashari UC, Khanduri S, Saxena S, Bhadury S. Gossypiboma: an important preventable cause of morbidity. *Ann Trop Med Pub Health*. 2012; 5: 397-399. <https://goo.gl/NdvEn1>
87. Shyung LR, Chang WH, Lin SC, Shih SC, Kao CR, Chou SY. Report of gossypiboma from the standpoint in medicine and law. *World J Gastroenterol*. 2005; 11: 1248-1249. <https://goo.gl/Bi9ajP>
88. Gümüş M, Gümüş H, Kapan M, Önder A, Tekbas G, Baç B. A serious medicolegal problem after surgery: gossypiboma. *Am J Forensic Med Pathol*. 2012; 33: 54-57. <https://goo.gl/aVAbMc>
89. Greenberg CC, Regenbogen SE, Lipsitz SR, Diaz-Flores R, Gawande AA. The frequency and significance of discrepancies in the surgical count. *Ann Surg*. 2008; 248: 337-341. <https://goo.gl/8P5zD6>
90. Yildirim S, Tarim A, Nursal TZ, Tulin Yildirim, Kenan Caliskan, Nurkan Torer, et al. Retained surgical sponge (gossypiboma) after intraabdominal or retroperitoneal surgery: 14 cases treated at a single center. *Langenbecks Arch Surg*. 2006; 391: 390-395. <https://goo.gl/q7Mzmo>
91. Lata I, Kapoor D, Sahu S. Gossypiboma, a rare cause of acute abdomen: a case report and review of literature. *Int J Crit Illn Inj Sci*. 2011; 1: 157-160. <https://goo.gl/vC4Jsh>
92. Asuquo ME, Ogbu N, Udosen J, Ekpo R, Agbor C, Ozinko M, et al. Acute abdomen from gossypiboma: a case series and review of literature. *Niger J Surg Res*. 2006; 8: 174-176. <https://goo.gl/vSyOC3>
93. Gencosmanoglu R, Inceoglu R. An unusual cause of small bowel obstruction: Gossypiboma—case report. *BMC Surg*. 2003; 3: 6. <https://goo.gl/URXDF2>
94. Sistla SC, Ramesh A, Karthikeyan VS, Ram D, Ali SM, Subramaniam RVS. Gossypiboma presenting as coloduodenal fistula—report of a rare case with review of literature. *Int Surg*. 2014; 99: 126-131. <https://goo.gl/RbEs1f>
95. Grassi N, Cipolla C, Torcivia A, Bottino A, Fiorentino E, Ficano L, et al. Trans-visceral migration of retained surgical gauze as a cause of intestinal obstruction: a case report. *Journal of Medical Case Reports*. 2008; 2: 17. <https://goo.gl/HbZ9Ku>
96. Mahalik SK, Gupta SK, Khanna AK. Gossypiboma: intramural and transmural migration causing small bowel obstruction. *ANZ J Surg*. 2008; 78: 417-418. <https://goo.gl/jyJfGT>
97. Colak T, Olmez T, Turkmenoglu O, Dag A. Small bowel perforation due to gossypiboma caused acute abdomen. *Case Rep Surg*. 2013; 219354. <https://goo.gl/SrEzU3>
98. Kumar B, Kumar P, Sinha SK, Sinha N, Hasan Z, Thakur VK, et al. Gossypiboma mimicking posterior urethral stricture. *Int J Surg Case Rep*. 2013; 4: 425-428. <https://goo.gl/b8gjGc>
99. Anjum MR. Gossypiboma (retained surgical sponge) manifesting 6 years after pyelolithotomy. *NMJ*. 2009; 1: 29-31.
100. Apter S, Hertz M, Rubinstein ZJ, Zissin R. Gossypiboma in the early post-operative period: a diagnostic problem. *Clin Radiol*. 1990; 42: 128-129. <https://goo.gl/9FY1co>
101. Karasaki T, Nomura Y, Nakagawa T, Tanaka N. Beware of gossypibomas. *BMJ Case Rep*. 2013. <https://goo.gl/DP7x4S>
102. Rehman A, Baloch NU, Awais M. Gossypiboma diagnosed fifteen years after a cesarean section: A case report. *Qatar Med J*. 2014; 2014: 65-69. <https://goo.gl/X6YMis>

103. Sheward SE, Williams Jr AG, Mettler Jr FA, Lacey SR. CT appearance of a surgically retained towel (gossypiboma). *J Comput Assist Tomogr.* 1986; **10**: 343–345. <https://goo.gl/dnmges>
104. Martins MCB, Amaral RPG, Andrade CS, Lucato LT, Leite CDC. Magnetic resonance imaging findings of intracranial gossypiboma: a case report and literature review. *Radiologia Brasileira.* 2009; **42**: 407–409. <https://goo.gl/zEAcSB>
105. Manzella A, Filho PB, Albuquerque E, Farias F, Kaercher J. Imaging of gossypibomas: pictorial review. *AJR Am J Roentgenol.* 2009; **193**: S94–101. <https://goo.gl/bVBJhp>
106. Kopka L, Fischer U, Gross AJ, Funke M, Oestmann JW, Grabbe E. CT of retained surgical sponges (textilomas): pitfalls in detection and evaluation. *J Comput Assist Tomogr.* 1996; **20**: 919–923. <https://goo.gl/HBh3MY>
107. Malik A, Jagmohan P. Gossypiboma: US and CT appearance. *Indian J Radiol Imaging.* 2002; **12**: 503–504. <https://goo.gl/4EXxmB>
108. O'Connor AR, Coakley FV, Meng MV, Eberhardt S. Imaging of retained surgical sponges in the abdomen and pelvis. *AJR Am J Roentgenol.* 2003; **180**: 481–489. <https://goo.gl/Kmxszz>
109. Lu YY, Cheung YC, Ko SF, Ng SH. Calcified reticulate rind sign: a characteristic feature of gossypiboma on computed tomography. *World J Gastroenterol.* 2005; **11**: 4927–4929. <https://goo.gl/j9Q5oK>
110. Yadav MK, Lal A, Nagi B. Gossypiboma: stretched feces sign. *AJR Am J Roentgenol.* 2010; **195**: W375. <https://goo.gl/pvhSUC>
111. Singh R, Mathur RK, Patidar S, Tapkire R. Gossypiboma: its laparoscopic diagnosis and removal. *Surg Laparosc Endosc Percutan Tech.* 2004; **14**: 304–305. <https://goo.gl/nR4HLi>
112. Uluçay T, Dizdar MG, SunayYavuz M, Aşirdizer M. The importance of medico-legal evaluation in a case with intraabdominal gossypiboma. *Forensic Sci Int.* 2010; **198**: e15–e18. <https://goo.gl/gyNUAb>
113. Rogers A, Jones E, Oleynikov D. Radio frequency identification (RFID) applied to surgical sponges. *Surg Endosc.* 2007; **21**: 1235–1237. <https://goo.gl/xG6X28>
114. Macario A, Morris D, Morris S. Initial clinical evaluation of a handheld device for detecting retained surgical gauze sponges using radiofrequency identification technology. *Arch Surg.* 2006; **141**: 659–662. <https://goo.gl/bLekCT>
115. Kranzfelder M, Zywitzka D, Jell T, Schneider A, Gillen S, Friess H, et al. Real-time monitoring for detection of retained surgical sponges and team motion in the surgical operation room using radio-frequency-identification (RFID) technology: a preclinical evaluation. *J Surg Res.* 2012; **175**: 191–198. <https://goo.gl/eNhuZQ>
116. Greenberg CC, Diaz-Flores R, Lipsitz SR, Regenbogen SE, Mulholland L, Mearn F, et al. Bar-coding surgical sponges to improve safety: a randomized controlled trial. *Ann Surg.* 2008; **247**: 612–616. <https://goo.gl/sA4b8b>
117. Regenbogen SE, Greenberg CC, Resch SC, Kollengode A, Cima RR, Zinner MJ, et al. Prevention of retained surgical sponges: a decision-analytic model predicting relative cost-effectiveness. *Surgery.* 2009; **145**: 527–535. <https://goo.gl/RuaAHP>