



# Open Journal of Surgery

## Research Article

# Inguinal Hernias Repair by Plasty of External Oblique Aponeurosis (Desarda Technique): An Alternative to Prosthetic Repair in Developing Countries -

**Mamadou Seck\***, Mamadou Cisse, Alpha Oumar Toure, Ibrahima Ka, Ousmane Ka and Madieng Dieng

General Surgery Department, University Hospital Aristide Le Dantec, Dakar, Senegal

**\*Address for Correspondence:** Mamadou Seck, General Surgery Department, University Hospital Aristide Le Dantec, Dakar, Senegal, E-mail: seckmad@gmail.com

**Submitted:** 16 April 2020; **Approved:** 27 June 2020; **Published:** 29 June 2020

**Cite this article:** Seck M, Cisse M, Toure AO, Ka I, Ka O. Inguinal Hernias Repair by Plasty of External Oblique Aponeurosis (Desarda Technique): An Alternative to Prosthetic Repair in Developing Countries. Open J Surg. 2020;4(2): 037-041.

**Copyright:** © 2020 Seck M, et al. This is an open access article distributed under the Creative Commons Attribution License, which permits unrestricted use, distribution, and reproduction in any medium, provided the original work is properly cited.

## ABSTRACT

Desarda technique is autoplasic method using the external oblique aponeurosis in the treatment of inguinal hernias.

**Aim:** To report our experience using this technique in the treatment of inguinal hernias in adults.

**Patients and methods:** This is a prospective descriptive study of 4 years (March 2009-March 2013) on 115 cases of inguinal hernia by fascial plasty of external oblique muscle. There were 100 men (94.8 %) and 6 women (5.2%) with a mean age of 42.7 years.

**Results:** Spinal anesthesia was used in 90 cases (86.1 %). The average operative time was 34.8 minutes. The evaluation of pain beyond the third month has noted 12 cases (11.3%) of mild chronic pain (VAS < 2). Two cases of recurrence (1.7%) were noted in our study. The average being decline was 33.08 months (2.75 years).

**Conclusion:** The aponevrotic plasty according to Desarda constitute an alternative to cures for prosthesis in the treatment of inguinal hernias.

**Keyword:** Inguinal hernia; Aponevrotic plasty; Chronic pain; Recurrence

## INTRODUCTION

History of inguinal hernia pathology have knew many repair techniques [1]. Lichtenstein technique, being a tension-free repair, is considered the « gold standard » [1]. The plasty by aponevrotic flap is also a tension-free process because its rate of recurrence and chronic pain are similar to those of prosthetic plasty with more an operating lower direct cost [2,3,4]. However, none of these techniques is subject to a real consensus. The objective of this study is to report our experience of using this technique in the treatment of inguinal hernias in adults in order to propose it as an alternative. The parameters studied were the operative data, chronic pain and recurrence.

## PATIENTS AND METHODS

### Study framwork

This is a prospective study of 4 years (March 2009-March 2013), with 115 cases of uncomplicated inguinal hernia repair, by aponevrotic plasty of external oblique muscle (Desarda technique) in General Surgery Department of the University Hospital Aristide Le Dantec. The data were analyzed by the software Epi-Info and Excel.

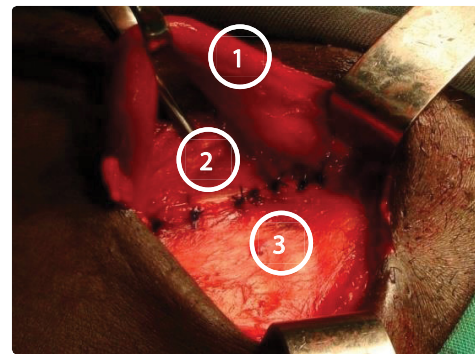
### Patients

They were 100 men (94.8%) and 6 women (5.2%), with mean age of 42,7ans with extremes of 18 years and 78ans. The hernia was unilateral in 97 cases (91.5%) and bilateral in 9 cases (8.5%). Were excluded from the study patients with prostatic disease, strangulated and recurrent hernias.

### Surgical technique

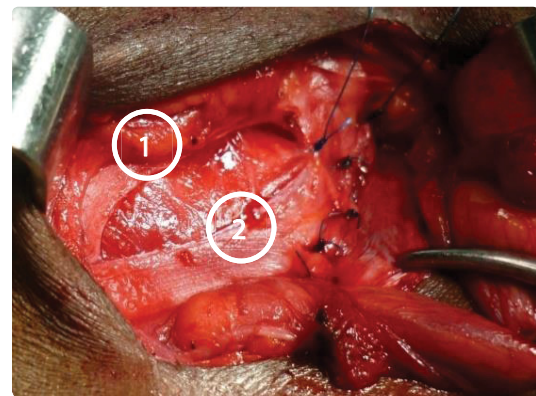
Installation was made on ordinary operating table. After general or locoregional anesthesia and transverse incision inguinal, the technique begins by an opening of the External Oblique Aponeurosis (EOA) in parallel to the inguinal ligament. This opening creates 2 lips, Medial Lip (ML) and Lateral Lip (LL). The second time of the operation is a suture of the medial lip of fascia on the Inguinal Ligament (IL) with a continuous non-absorbable sutures (Figure 1). The third time is an incision of fascia sutred to 1 or 1.5 cm of suture line, allowing to have a fascial flap and a new medial lip (Figure 2).

The fourth time is suture of the free edge of the flap on the joint tendon or internal oblique muscle (Figure 3) and the last time a suture of the external lip and the new medial lip of the EOA forward spermatic cord by a suture of absorbable thread (Figure 4). The operation ends with skin closure.



**Figure 1:** ML sutured in IL [9].

1. Spermatic cord
2. Inguinal ligament
3. Medial lip sutured



**Figure 2:** Incision of OEA sutured [9]

1. New medial lip
2. Fascial flap

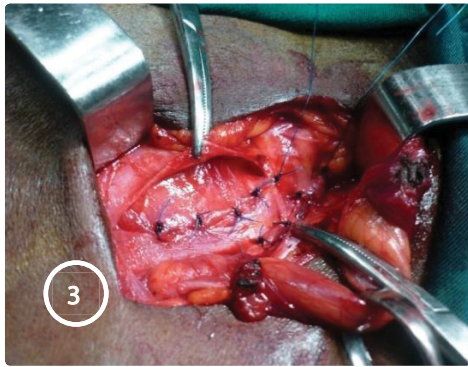
### Evaluation of pain

Chronic pain was evaluated by Visual Analogic Scale (VAS).

## RESULTS

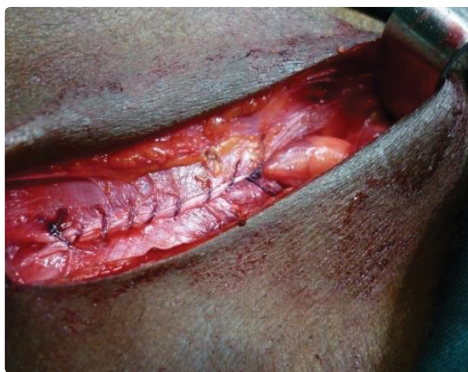### Type of d'anesthesia

Spinal Anesthesia (SA) was used in 90 cases (85%) and General Anesthesia (GA) in 16 cases (15%). No patient were operated under Local Anesthesia (LA).



**Figure 3:** : Suture of the free edge of flap [9].

1. New medial lip,
2. Fascial flap sutured,
3. Spermatic cord



**Figure 4:** Aponevrotic closure [9].

**Operative time**

The mean operative time was 34,8 minutes with extremes of 10 minutes and 95 minutes.

**Morbidity**

Nine patients had presented an early postoperative complications. It was about 4 cases (3,8%) of wound infection, 2cases (1,9%) of scrotal hematoma and 3 cases (2,8%) of urinary retention. Acute postoperative pain was noted in 45 patients (42,4%) in the first postoperative day, in 24 patients (22,6%) in the second postoperative day and in 12 patients (11,3%) in third postoperative day. Chronic pain (>3month) was presents in 12 cases (11,3%). The pain was minimal (VAS between 1 and 2) with a follow-up between 11 months and 55 months (Table 1). Two cases (1,7%) of recurrence were recorded with a respective follow-up of 26 months and 34 months. The average of follow-up was 33.1% (2.75 years).

**DISCUSSION**

**Surgical technique**

Desarda technique is a closure of the posterior wall of the inguinal canal by a flap of the EOA (Figure 5). It is a «tension free » process that does not require a great surgical experience and can be made with only 2 threads (1 absorbable and 1 nonabsorbable). Another advantage of this technique is the absence of prosthetic use so of foreign body [2,4].

Eighty five percent of our patients were operated under SA. Desarda has used the SA in 92.5% of cases in this technique [5]. However, it's possible to carry out this technique under local anesthesia [5].

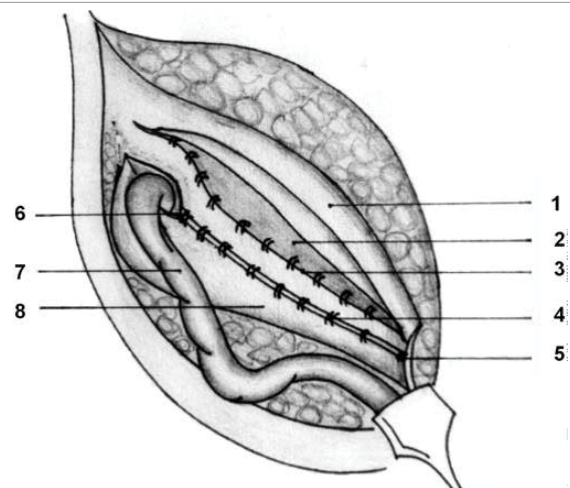
The mean of operative time in our study was very high compared to those of Manyilirah and al, both for Desarda technique (10 minutes) and Lichtenstein technique (15.9 minutes) [6]. But according to the literature, our average operative time was comparable to those prosthetic repair, including laparoscopic and was well below those of hernioraphy (Bassini and Shouldice) [7, 8]. The difference can be explained by the fact that in our study, it involves the entire surgery, contrary to the cited authors wich took into account only the main surgical act.

**Morbidity**

The rate of wound infection in our study was comparable to that of the first serie reported by Dieng and al. [4]. This result is very high compared with those of 2 series of Desarda who noted this complication in respectively 0.6% and 1%. This significant difference can be explained by the fact that the author used antibiotic prophylaxis, which was not the case in our study [2]. The infection

**Table1 :** Chronic pain.

Following-up (months)	VAS (≤ 2)	Number	Percentage (%)
11 a 48	1	9	8,5
33 a 55	2	3	2,8
6 a 48	0	94	88,7
Total	0 a 2	106	100



**Figure 5:** Undetached strip of the external oblique aponeurosis forming the posterior wall [5]

- 1 Reflected medial leaf after a strip has been separated,
- 2 internal oblique muscle seen through the splitting incision made in the medial leaf,
- 3 interrupted sutures between the upper border of the strip and conjoined muscle and internal oblique muscle,
- 4 interrupted sutures between the lower border of the strip and the inguinal ligament,
- 5 pubic tubercle,
- 6 abdominal ring,
- 7 spermatic cord,
- 8 lateral leaf.



would be favored by the anterior approach and degree of dissection, but also by frequent aseptic mistakes in our context. She is almost nil in the treatments by posterior approach [7] and frequent in prosthetic treatments by anterior approach [9]. Scrotal hematoma was 1.9% in our study. This rate comparable to that of the first serie described by Dieng and al, was significantly higher than those of the 2 series of Desarda [2,4]. The hematoma would be linked to a problem of hemostasis secondary to extensive dissection [10]. Pathophysiology of acute post-operative pain does not seem influenced by the surgical technique. Situma, in a comparative study, obtained a comparable rate of acute pain between Desarda and Bassini techniques, despite the extensive dissection in the herniorrhaphy [11]. Similar results were reported by Desarda in its 2 series [2,5]. Acute pain was also similar between Desarda and Lichtenstein techniques [6]. Analysis of these results show that acute pain is more related to the operative wound and is therefore not a good criterion of technical anterior approaches.

### Chronic pain

According to some authors, there are mainly two types of chronic pain after inguinal hernia repair: nociceptive pain linked to tissue trauma and neuropathic pain due to direct damage of the ilioinguinal nerve, iliohypogastric nerve and genital branch of genito-femoral nerve [12,13]. The study of chronic pain has been simplified by the Cunningham team which classified into 3 types: somatic pain (tissue tension), neuralgic pain (nerve injury) and visceral pain (obstruction of the vas deferens tube by scar fibrosis) [14]. According to this theory, the conventional processes (Bassini, Shouldice and Mac Vay) caused more chronic pain because they associate these three mechanisms [15]. In the literature, the rate of chronic pain in this techniques varies between 0 and 53% in herniorrhaphies [10,13]. The processes by aponevrotic plasty, despite their anterior approach, have chronic pain rate very low, comparable to laparoscopic technique. Indeed, in their study on the plasty by the rectus muscle aponeurosis (Vayre Petit Pazos technique), Phe et al. Only 3.7% reported chronic pain with a mean follow-up of 8 months [16]. This low incidence of residual pain in aponevrotic plasties, have an anatomical and physiological explanation. Anatomically, the technique does not expose iliohypogastric and ilioinguinal nerves to compression sutures as in the Lichtenstein technique. Physiologically, the scarring fibrosis is in the heart of the painful phenomena in hernia repair. This fibrosis is particularly important in extensive dissection, especially when a foreign body is used. [17]. According recent publications, the prosthesis causes progressive scarring fibrosis that can injure the nerves of the inguinal region. This phenomenon is the cause of the frequency of late pain in anterior hernioplasties [16]. Our results were higher (11.3%) compared to literature but the pain was mild (VAS between 1 and 2) in all cases. However, the lowest rates of chronic pain remain the fact of laparoscopic techniques [17].

### Recurrence

According Barrier and al, the recurrence rate depends on the time elapsed after surgery. In a study of 1474 patients, he reported 42% recurrence at 2 years, 34% at 5 years and 19% over 20 years [18]. Several studies were done on the recurrence rate of inguinal hernia repair. Conventional techniques making with tension sutures, lead to more of recurrence, with rates ranging between 6.1% and 11.2% after a mean follow-up of 8.5 years [10]. Prosthetic repair cause to less recurrence. George and al. reported a recurrence rate of 0.2% in a retrospective study of 540 patients operated by the Lichtenstein technique with a follow-up of 3.8 years [19]. Similar results were reported by most

authors [8,20,21]. In the study of Phe and al, the plasty with rectus muscle aponeurosis had a similar rate to prosthetic techniques (1.2% recurrence) with a follow-up of 71 months [16]. Recurrence rate was similar in our study with a recurrence rate to 1.8% and the follow-up was 33 months. Desarda, pioneer of the technique, observed one case of recurrence (0.25%) with a follow-up of 24 months in its first serie and not recorded recurrence in its second serie with more operated patients (860 patients) and a larger average follow-up of 96.6 months [2,5]. These results are explained by the anatomic and physiological principle of aponevrotic plasty. Anatomically, as all plasties, the Desarda possess is to close of the posterior wall of the inguinal canal without tension [5]. Physiologically, the intra-abdominal pressure is the main mechanism involved in prosthetic repair because it is this pressure that folds the prosthesis against the abdominal wall in the posterior approach techniques (Laparoscopy). In contrary, the Lichtenstein technique does not involve this phenomenon, due to the superficial position of the prosthesis [22]. In Desarda tehniqe, the aponevrotic flap prevents recurrence by dynamic mechanisms that corrects the deficit of aponevrotic extensions by muscular contractions [5]. The use of the aponeurosis as material of plasty, regardless of patient age, is a safe attitude, because the aging process is minimal in the fascia and tendons [2].

### CONCLUSION

Desarda technique is an autoplasty by external oblique aponeurosis. In vew of its results, it is an alternative solution to Lichtenstein technique, especially as it is a physiological response to pathogenesis of inguinal hernia.

### REFERENCES

1. Pelissier E, Palot JP, Ngo P. Traitement chirurgical des hernies inguinales par voie inguinale. Encyclopedie Médico-Chirurgicale -Techniques chirurgicales - Appareil digestif. 2008; 40:110.
2. Desarda MP. New method of inguinal hernia repair. ANZ J Surg. 2001; 71: 241-244. DOI: 10.1046/j.1440-1622.2001.02092.x
3. Desarda MP. Surgical physiology of inguinal hernia repair - a study of 200 cases. BMC Surgery. 2003; 3: 2. DOI: 10.1186/1471-2482-3-2
4. Dieng M, Cisse M, Seck M, Diallo FK, Toure AO, Konate I, et al. Cure des hernies inguinales simples de l'adulte par plastie avec l'aponévrose du grand oblique : technique de Desarda. e-mémoires de l'Académie Nationale de Chirurgie. 2012 ; 11: 069-074.
5. Desarda MP. Physiological repair of inguinal hernia: a new technique (study of 860 patients). Hernia. 2006; 10: 143-146. DOI: 10.1007/s10029-005-0039-1
6. Manyilirah W, S Kijjambu, A Upoki, J Kiryabwire. Comparison of non-mesh (desarda) and mesh (lichtenstein) methods for inguinal hernia repair among black african patients: a short-term double-blind RCT. Hernia. 2012 ; 16 : 133-44. DOI: 10.1007/s10029-011-0883-0
7. Farthouat P, Ogoubemy M, Diouf MB. Abord coelioscopique des hernies inguinales: Expérience l'hôpital de Dakar. Le journal de Coélio-chirurgie. 2005; 55: 63-66.
8. Phatchara H, Chumpon W, Kunlanid C, Nateecha P, Oraphan P, Ninatthanan P. comparative study of tailor-made mesh plug herniorrhaphy versus lichtenstein herniorrhaphy versus bassini operation: A prospective clinical trial. Asian J Surg. 2006; 29: 74-78. DOI: 10.1016/S1015-9584(09)60111-1
9. Fawole AS, Chaparala RCP, Ambrose NS. Fate of the inguinal hernia following removal of infected prosthetic mesh. Hernia. 2006; 10: 58-61. <https://bit.ly/3i2qsWW>
10. Hay JM, Boudet MJ, Fingerhut A. Shouldice inguinal hernia repair in the male adult: the gold standard? A multicenter controlled trial in 1578 patients. Ann Surg. 1995; 222: 719-727. DOI: 10.1097/0000658-199512000-00005
11. Situma SM, Kaggwa S, Masiira NM, Mutumba SK. Comparison of De sarda

- versus modified bassini inguinal Hernia Repair: A Randomized controlled trial. *East and Central African Journal of Surgery*. 2009; 14: 2.
12. Aasvang EK, Bay Nielsen M, Kehlet H. Pain and functional impairment 6 years after inguinal herniorrhaphy. *Hernia*. 2006; 10: 316-21. DOI: 10.1007/s10029-006-0098-y
  13. Poolbalan AS, Bruce J, Smith WC, King PM, Krukowski ZH, Chambers WA. A Review of chronic pain after inguinal herniorrhaphy. *Clin J Pain*. 2003; 19: 48-54. DOI: 10.1097/00002508-200301000-00006
  14. Cunningham J, Temple WJ, Mitchell P, Nixon JA, Preshaw RM, Hagen NA. Cooperative hernia study: Pain in the post-repair patient. *Ann Surg*. 1996; 224: 598-560. DOI: 10.1097/00000658-199611000-00003
  15. Desarda MP, Ghosh A. Comparative study of open mesh repair and Desarda's No-Mesh repair in a district hospital in India. *East and Central African Journal of Surgery*. 2006; 11: 2.
  16. Phe V, Bitker MO, Misrai, Richard F. Cure de hernie inguinale selon la technique de Vayre Petit Pazos : Étude rétrospective à propos de 83 patients consécutifs. *E-mémoires de l'Académie Nationale de Chirurgie*. 2008; 7: 26-32.
  17. Liem (108) MSL, Graaf YVD, Steensel CJV, Boelhouwer RU, Clevers GJ, Meijer WS et al. Comparison of conventional anterior surgery and laparoscopic surgery for inguinal hernia repair. *N Engl J Med*. 1997; 336: 1541-1547. DOI: 10.1056/NEJM199705293362201
  18. Barrier A, Bounekar A, Boelle PY, Houry S, Lacaine F, Huguier M. Hernies inguinales : Délais d'apparition des récurrences. *Journal de Chirurgie Viscérale*. 2007; 144: 125-127. <https://bit.ly/3eF920F>
  19. George HS, Ioannis H, Christos N, Nikolaos K, Alexios S, Constantinos A, et al. Open tension free repair of inguinal hernias; the Lichtenstein technique. *BMC Surgery*. 2001; 1: 3. DOI: 10.1186/1471-2482-1-3
  20. Cisse M, Sylla MS, Konate I, Tendeng J, Ka O, Dieng M, et al. La cure en 1 temps des hernies inguinales bilatérales par la technique de Lichtenstein. *J Afr Chir Digest*. 2010; 1: 1090-1093. <https://bit.ly/2VqVRZx>
  21. Marre P, Damas JM, Penchet A, Pélissier EP. Traitement de la hernie inguinale de l'adulte : Resultats des réparations sans tension. *Ann Chir*. 2001; 126:644-648. <https://bit.ly/2YCgm7v>
  22. Nyhus LM. The recurrent groin hernia: therapeutic solutions. *World J Surg*. 1989; 13: 541-544. DOI: 10.1007/BF01658868