



# American Journal of Urology Research

## Case Report

# What shall we do for Bilateral Undescended Testes Detected in a 21-Year-Old Male? - ㉓

Jong Kwan Park<sup>1</sup>, Myung Ki Kim<sup>1</sup>, Jae Hyung You<sup>1</sup>, Hyung Sub Park<sup>2</sup>, Yu Seob Shin<sup>1\*</sup>

<sup>1</sup>Department of Urology, Chonbuk National University Medical School, Jeonju, Korea

<sup>2</sup>Department of Surgery, Seoul National University Bundang Hospital, Seoul National University College of Medicine, Gyeonggi, Korea

\***Address for Correspondence:** Yu Seob Shin, Department of Urology, Chonbuk National University Medical School, and Research Institute of Clinical Medicine of Chonbuk National University-Biomedical Research Institute of Chonbuk National University Hospital, Jeonju, Korea, E-mail: ball1210@hanmail.net

**Submitted:** 14 July 2017; **Approved:** 18 July 2017; **Published:** 19 July 2017

**Citation this article:** Park JK, Kim MK, You JH, Park HS, Shin YS. What shall we do for Bilateral Undescended Testes Detected in a 21-Year-Old Male? Am J Urol Res. 2017;2(1): 010-012.

**Copyright:** © 2017 Ela WA, et al. This is an open access article distributed under the Creative Commons Attribution License, which permits unrestricted use, distribution, and reproduction in any medium, provided the original work is properly cited.

## ABSTRACT

Undescended Testis (UDT) is a common anomaly encountered in urology and is estimated to affect 1-4% of full term and up to 30% of preterm male neonates. We present a case of bilateral undescended testes detected in a 21-year-old male. On the routine hematological examination levels of serum tumor maker and hormone was within normal range. On the computed tomography scan of the abdomen with contrast demonstrated that both testes were on the inguinal area with no evidence of malignancy. The patients wanted to preserve his testes. Also, our medical team thought that preservation of testes is better option, to avoid hormone replacement therapy for his whole life. Finally, bilateral orchiopexy with herniorrhaphy was performed successfully. We gave him an education to perform a monthly testicular self-examination and an annual follow up in clinics due to high possibility of malignancy development than normal patients.

**Keywords:** Hormone; Malignancy; Undescended testis

## INTRODUCTION

Undescended Testis (UDT) is a common anomaly encountered in pediatric urology and is estimated to affect 1-4% of full term and up to 30% of preterm male neonates [1]. UDT, especially bilateral, is associated with impaired spermatogenesis, endocrine derangements and increased risk of testicular malignancy [1]. There is an emerging consensus among pediatric surgeons and urologists about the management of UDT with recommendations that the diagnosis of congenital UDT should be confirmed at 3-6 months of age and orchidopexy done at 6-12 months of age [2]. Unfortunately, in our case of bilateral UDT detected in a 21-year-old male. UDT is usually presenting in the newborn or during childhood, rarely diagnosed in the adult men. Here, we report of our experience of bilateral UDT, including its decision making process and treatment.

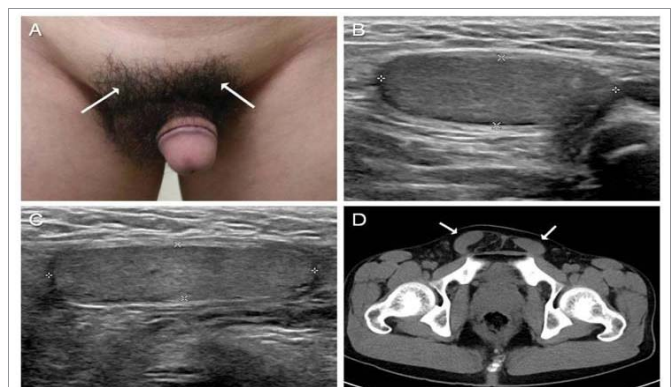
## CASE REPORT

A 21-year-old male was admitted to our department with complaints of shape of his both scrotum different from the other peers. He detected his difference while in the shower after sport games with his peers. On the physical examination, revealed an empty space of left scrotum and soft irreducible mass, thought to be an inguinal hernia at right scrotum without both testes (Figure 1A). Both testes were palpable at the bilateral inguinal area (Figure 1A). His height (163 cm) and weight (53 kg) were below average in his age group. He had normal penis and body hair. The patient had no specific prior medical and family history. He thought that soft irreducible mass due to right inguinal hernia was his testes. He had not sought medical attention. On the routine hematological labs, levels of serum tumor maker (alpha feto protein: 2.49 ng/ ml, human chorionic gonadotropin: 0.1 < mIU/ ml, lactate dehydrogenase: 171 IU/l) and hormone [Follicle Stimulating Hormone (FSH): 12.0 mIU/ ml, Luteinizing Hormone (LH): 9.8 mIU/ ml, testosterone: 10.86 ng/ ml, free testosterone: 15.96 pg/ ml] was within normal range. The semen analysis revealed his azoospermia (Semen color: creamy, amount: 4 ml, count: 0/ ml, motility: 0%, morphology 0%). On the Ultrasonography and computed tomography scan of the abdomen with contrast demonstrated that both testes were on the inguinal area (Left testis: 2.75 × 1.0 cm, Right testis: 3.66 × 0.9 cm,) with no evidence of malignancy and herniated omental fat was detected in the right scrotal sac (Figure 1B, C and D). There were a number of difficulties to make decision for his treatment. Because of high possibility of malignancy development than normal patients, it has to be removed? Otherwise, for preservation of his hormone function, it has to be preserved? The patient wanted to preserve his both testes. Also, our medical team thought that preservation of both testes is better option, to avoid hormone replacement therapy for his whole life. Moreover, his serum tumor markers were normal and CT scan demonstrated

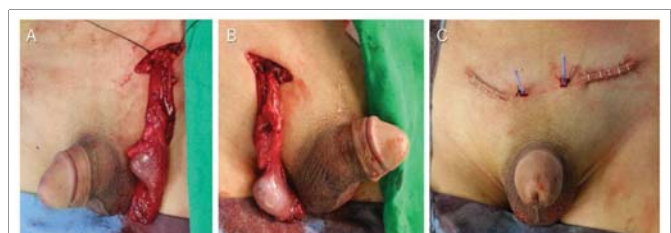no evidence of malignancy. Finally, bilateral orchiopexy with herniorrhaphy was performed successfully (Figure 2). Both spermatic cord with testes was fully dissected from surrounding structures and fixed at dartos pouch (Figure 2). We gave him an education to conduct annual follow up his testes in clinics due to high possibility of malignancy development than normal patients.

## DISCUSSION

Hormonal therapy for UDT has historically been described but since shown to have high recurrence rates with potential risk to testicular germ cells [3]. The orchidopexy is the gold standard of treatment for UDT, similar to other accepted guide-lines, and has been so for many years [3]. Despite this, a surprising proportion of respondents thought that either hormonal therapy or watchful



**Figure 1:** A: On physical examination, both testes (arrows) were palpable at the bilateral inguinal area (Left scrotum: empty space, Right scrotum: soft irreducible mass). Ultrasonography demonstrated that both testes were on the inguinal area with small and normal shape. B: left testis (size: 2.75 × 1.0 cm), (C) Right testis (size: 3.66 × 0.9 cm). D: Computed tomography scan of the abdomen with contrast demonstrated that both testis (arrows) was on the inguinal area with no evidence of malignancy and herniated omental fat was detected in the right scrotal sac.



**Figure 2:** Intra-operative findings, both spermatic cord with testis was fully dissected from surrounding structures, A: Lt testis with spermatic cord B: Right testis with spermatic cord. Post-op findings C: Both testes were fixed at dartos pouch.

waiting was acceptable as an initial treatment option. Unfortunately, in our case of bilateral UDT detected in a 21-year-old male. In literature of a unilateral UDT detected in adult, may treated by orchiectomy to prevent malignancy development [4,5]. However, if bilateral orchiectomy were performed, hormone replacement therapy for his whole life is needed. Also, he needs his testes for reproduction in near future. It was challenging to decide proper treatment for him.

The orchiopexy performed before puberty decreases the risk of testis tumor compared to those boys with UDT who undergo orchidopexy after puberty [6]. The UDT is one of the established risk factors for testicular tumor. The commonest malignancy noted in UDT is seminoma. However, in our patients, serum tumor maker and findings of imaging studies suggest of no evidence of malignancy.

The testes are the male gonad in male. Testes are components of both the reproductive system and the endocrine system. The primary functions of the testes are to produce sperm and to produce androgens, primarily testosterone. The fertility is impaired after both, unilateral or bilateral UDT. It has been quoted that around 90% of patients with untreated bilateral UDT ultimately develop azoospermia [7]. The reduced fertility has been ascribed to the reduction in the total number of germ cells and to defective pre-pubertal germ cell maturation [7]. As in the literature, in our patient, azoospermia was occurred. Serum levels of FSH, LH, and testosterone are considered to be markers of testicular function. A few studies have also been performed on UDT children, with somewhat contradictory outcomes. Christiansen, et al. [8] reported that there were no significant differences in these hormone levels on UDT boys compared with normal prepubertal boys, and there was no difference between unilateral and bilateral UDT. However, Longui et al. [9] reported that UDT boys under the age of 4 year had higher FSH levels than controls. While, androgens levels was normal and endocrine function was preserved in our patient. We gave our patient for full information and right of choice for his disease. The patients wanted to preserve his both testes. Also, our medical team thought that preservation of both testes is better option, to avoid hormone replacement therapy for his whole life.

In conclusions, we preserved both testes in both UDT in a 21-year-old male solider. It is important to give him an education to perform a monthly testicular self-examination and an annual follow up in clinics due to high possibility of malignancy development than normal patients.

## REFERENCES

1. Chung E, Brock GB. Cryptorchidism and its impact on male fertility: a state of art review of current literature. *Can Urol Assoc J.* 2011; 5: 210-214. <https://goo.gl/AvfSjN>
2. Hutson JM, Thorup J. Evaluation and management of the infant with cryptorchidism. *Curr Opin Pediatr.* 2015; 27: 520-524. <https://goo.gl/RwC1uS>
3. Kolon TF, Herndon CD, Baker LA, Baskin LS, Baxter CG, Cheng EY, et al. Evaluation and treatment of cryptorchidism: AUA guideline. *J Urol.* 2014; 192: 337–345. <https://goo.gl/GZ4GgB>
4. Hirabayashi T, Ueno S. Rare variant of inguinal hernia, interparietal hernia and ipsilateral abdominal ectopic testis, mimicking a spiegelian hernia. *Case report. Tokai J Exp Clin Med.* 2013; 38: 77–81. <https://goo.gl/AxWcwQ>
5. Arslan Y, Karaman K, Altintoprak F, Kahyaoglu Z, Zengin I, Uzunoglu MY, et al. Indirect inguinal hernia sac containing testis and spermatic cord in an adult patient with cryptorchidism. *J Surg Case Rep.* 2014; 2014: 017. <https://goo.gl/6ThmoA>
6. Gracia J, Sanchez Zalabardo J, Sanchez Garcia J, Garcia C, Ferrandez A. Clinical, physical, sperm and hormonal data in 251 adults operated on for cryptorchidism in childhood. *BJU Int.* 2000; 85: 1100-1103. <https://goo.gl/DtRD8K>
7. Hadziselimovic F, Herzog B. Importance of early postnatal germ cell maturation for fertility of cryptorchid males. *Horm Res.* 2001; 55: 6-10. <https://goo.gl/s9AQKC>
8. Christiansen P, Andersson AM, Skakkebaek NE, Juul A. Serum inhibin B, FSH, LH and testosterone levels before and after human chorionic gonadotropin stimulation in prepubertal boys with cryptorchidism. *Eur J Endocrinol.* 2002; 147: 95–101. <https://goo.gl/DsL1uG>
9. Longui CA, Arnhold IJ, Mendonca BB, D'Ostvaldo AF, Bloise W. Serum inhibin levels before and after gonadotropin stimulation in cryptorchid boys under age 4 years. *J Pediatr Endocrinol Metab.* 1998; 11: 687–692. <https://goo.gl/tFbepH>